

3D- GEPRINTE OSTEOTOMIEËN VAN DE ENKEL

Dr. Farhad Tajdar
Orthoclinic-Brugge
09/12/2023

Arthrose van de enkel

- Meer dan 80% posttraumatisch (fracturen, ligamentaire letsels)
- 15-20 jaar eerder symptomatisch dan heup- of knie-arthrose
- Vaak actieve en sportieve populatie (die ook actief wenst te blijven)
- Asymetrische arthrose
- Chirurgische behandeling van enkelarthrose

Gewrichtssparen

d

Arthrodesse/prothes

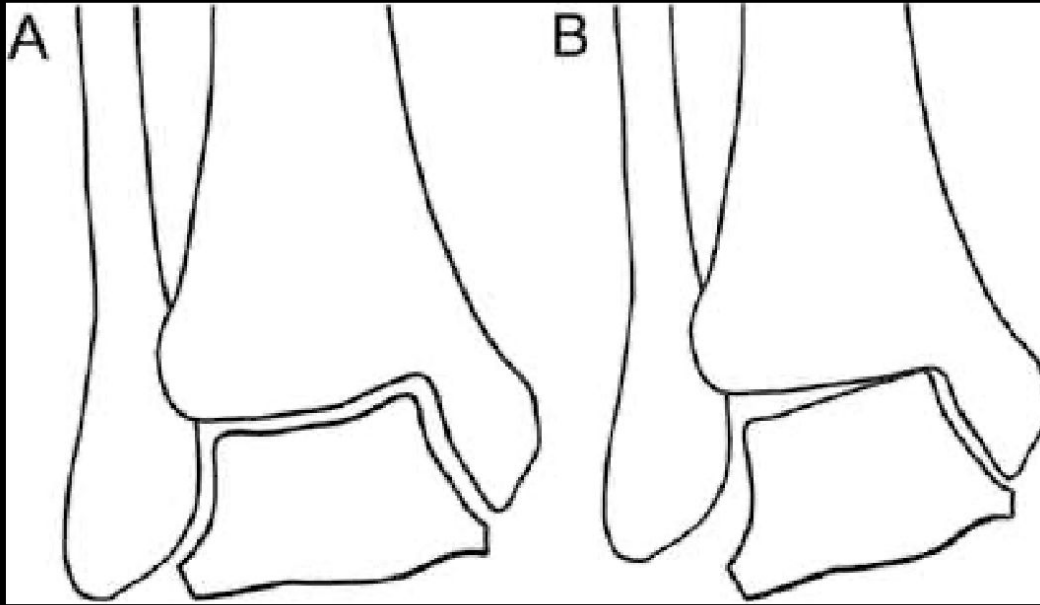
e

Hintermann B, Knupp M, Barg A.

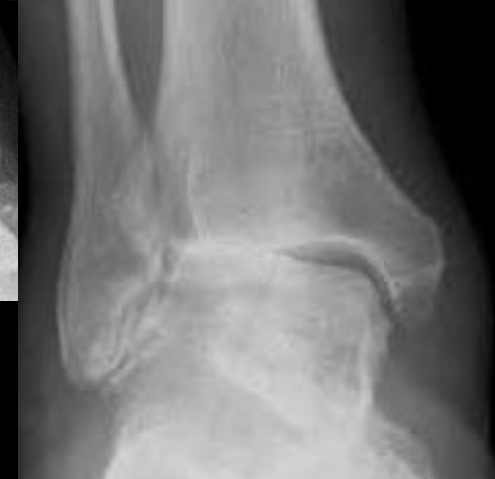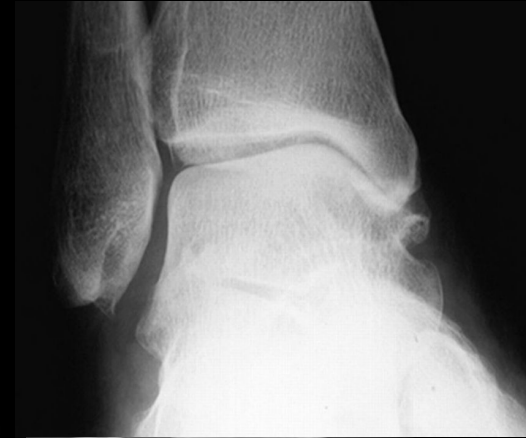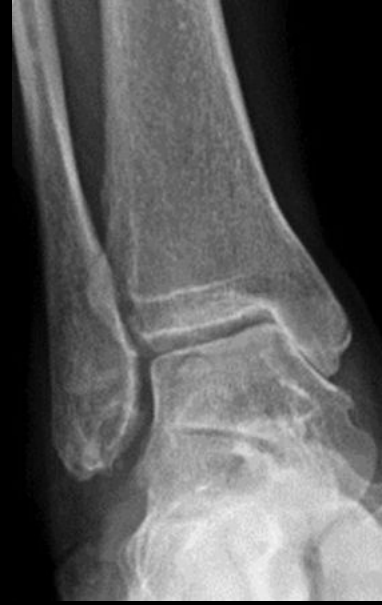Joint-preserving surgery of asymmetric ankle osteoarthritis with peritalar instability.

Foot Ankle Clin. 2013;18(3):503-516.

Asymmetrische arthrose

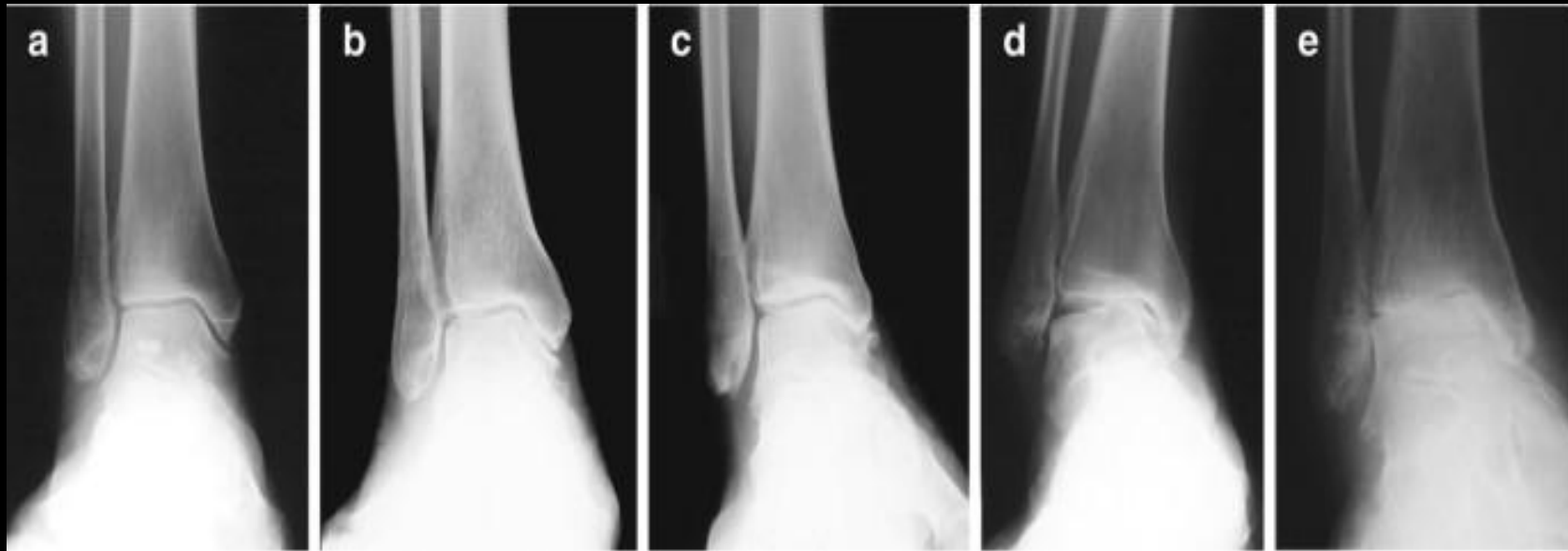

- A. Congruent: talus en tibia plafond parallel
 - B. Niet congruent: talus tilt (varus of valgus)
-

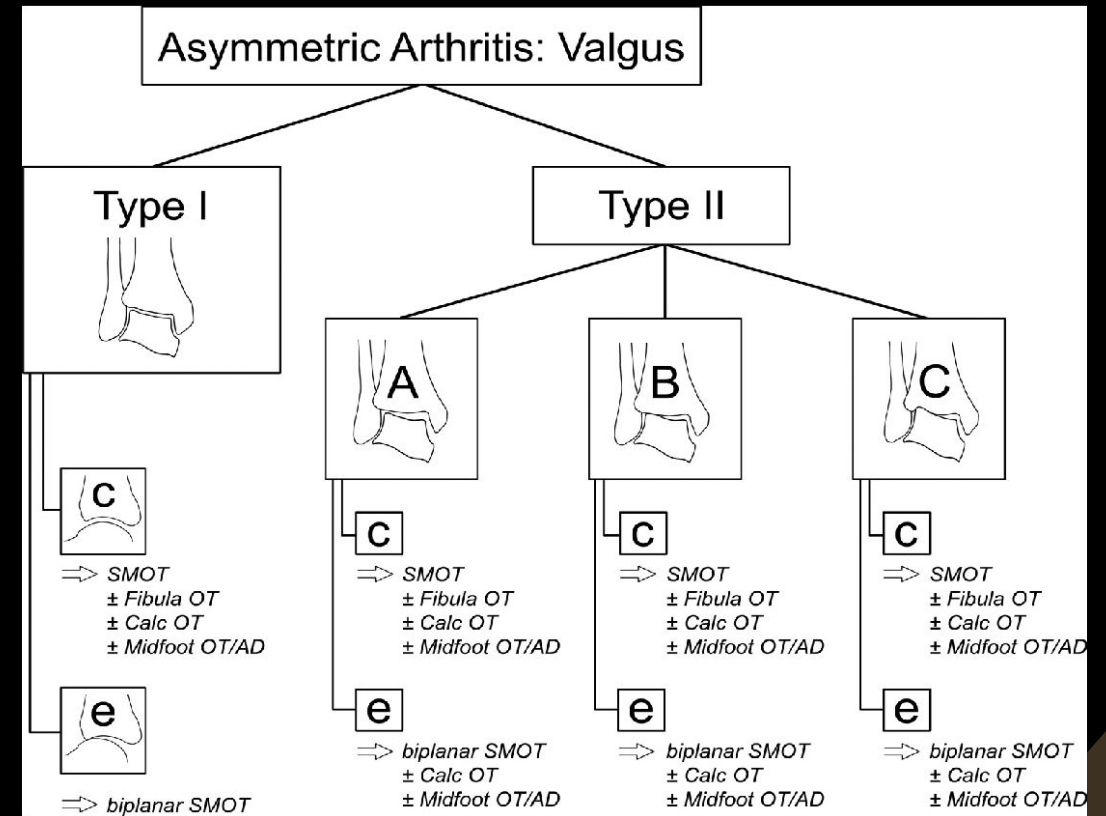
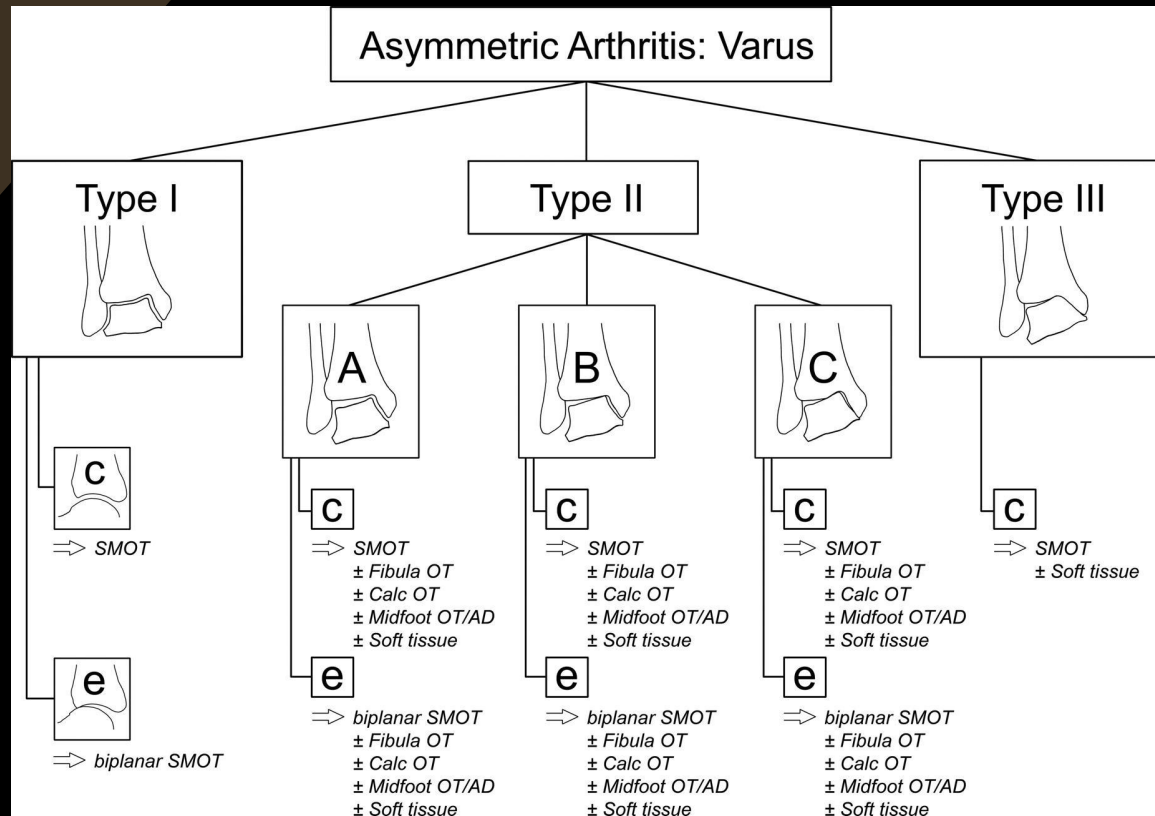


Asymmetrische Arthrose

Watanabe
classificatie



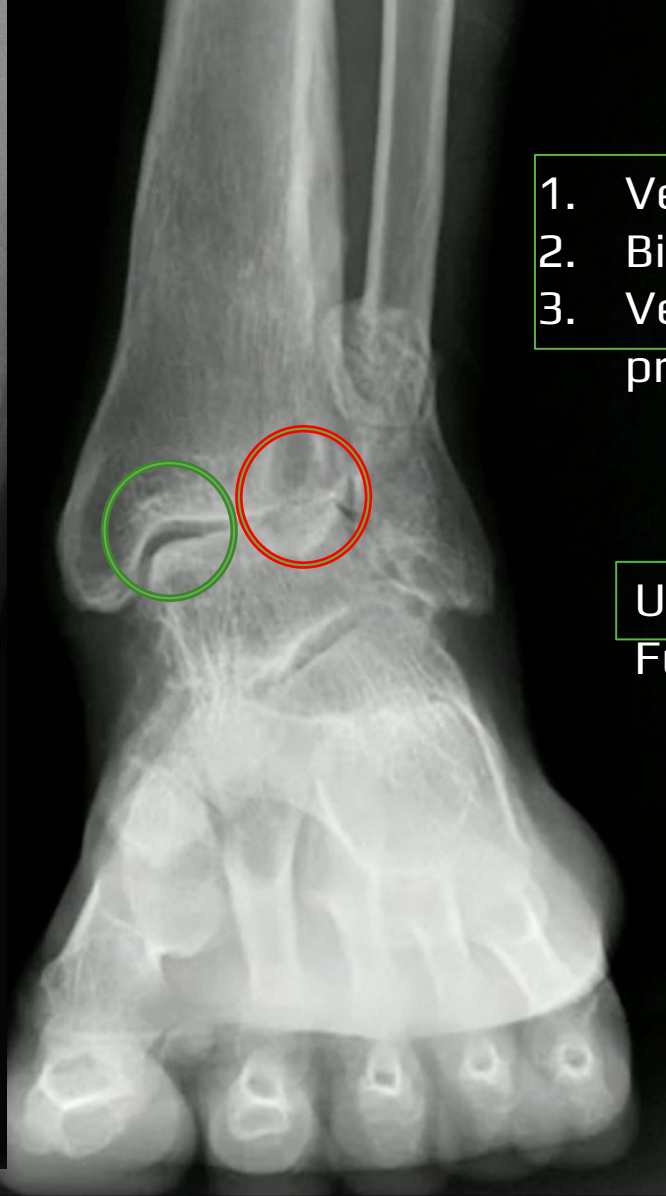
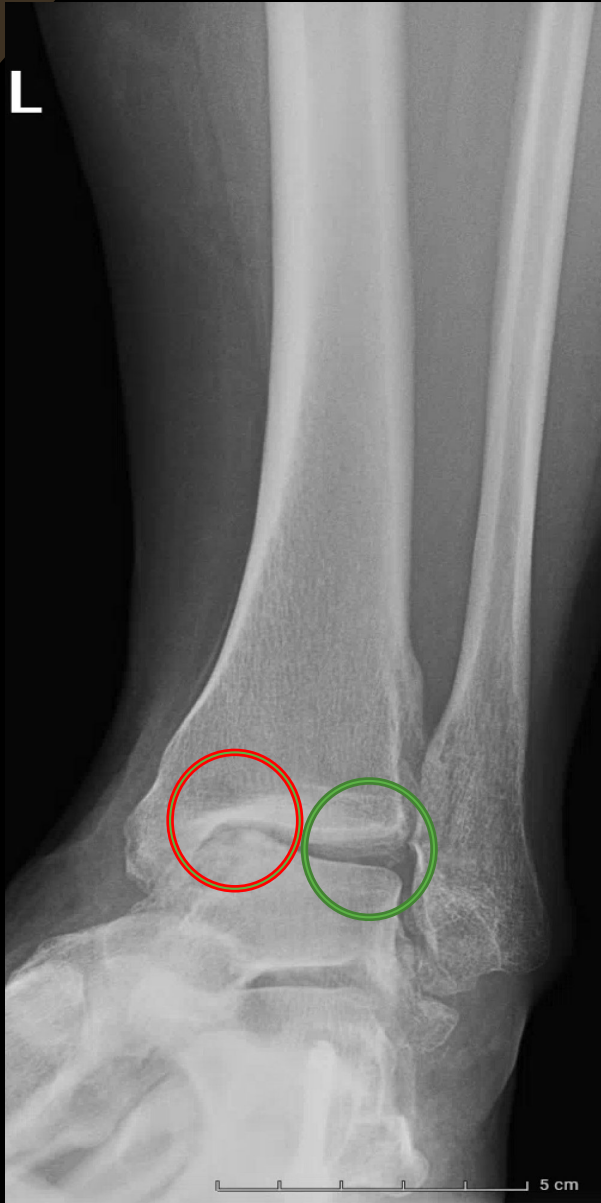Asymmetrische Arthrose



Markus Knupp, Sjoerd A S Stufkens, Lilianna Bolliger, Alexej Barg, Beat Hintermann

Classification and treatment of supramalleolar deformities

Foot Ankle Int. 2011 Nov;32(11):1023-31.

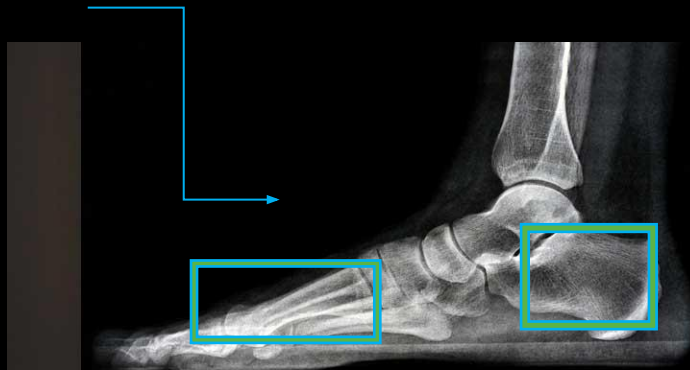
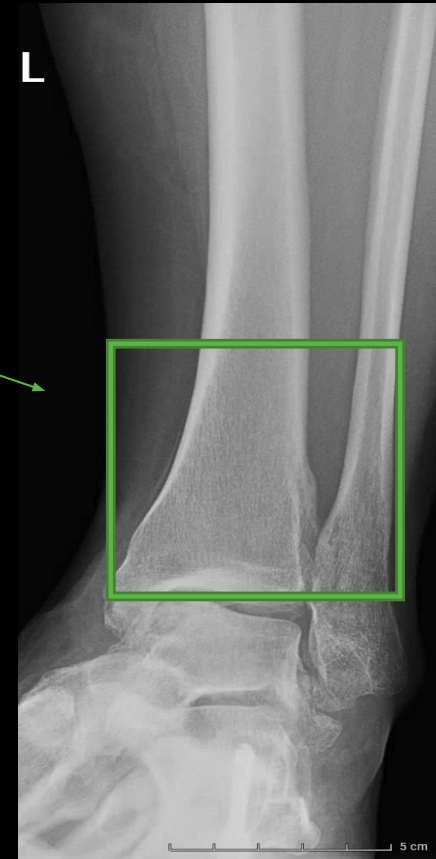


1. Verschuiven van de draagkracht
2. Biomechanica herstellen
3. Vertragen van het degeneratief proces

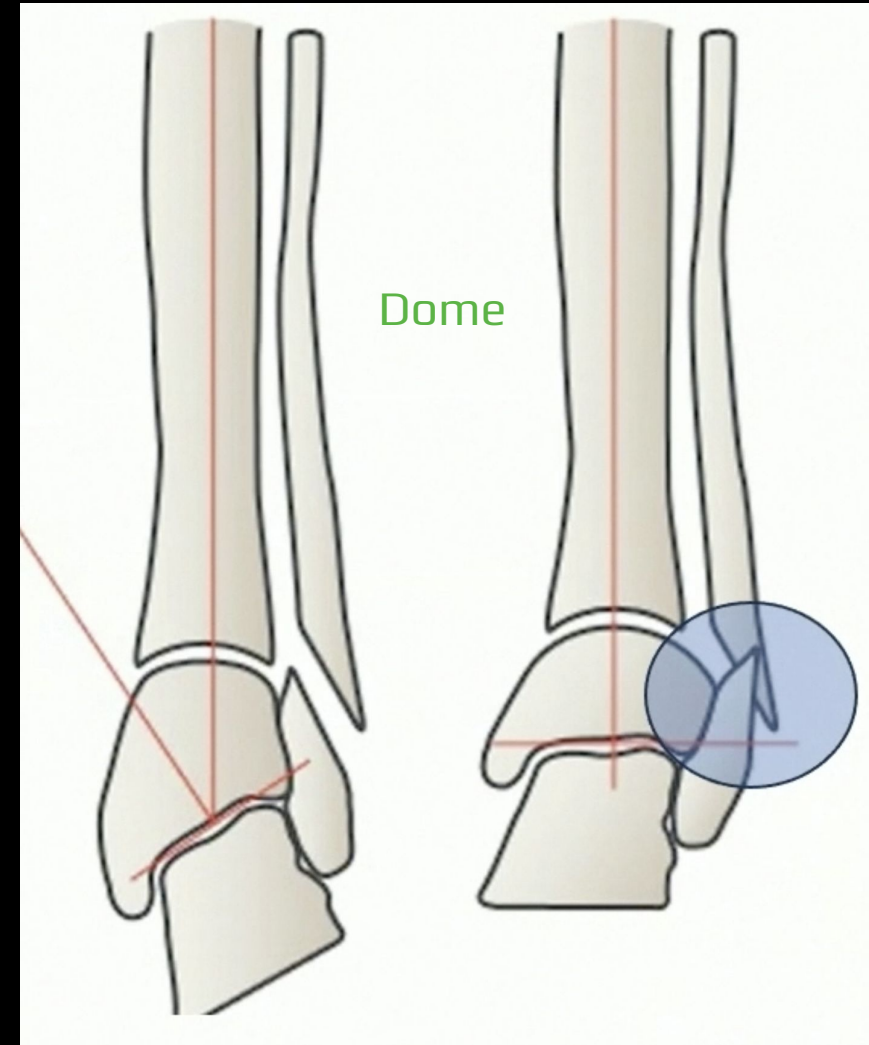
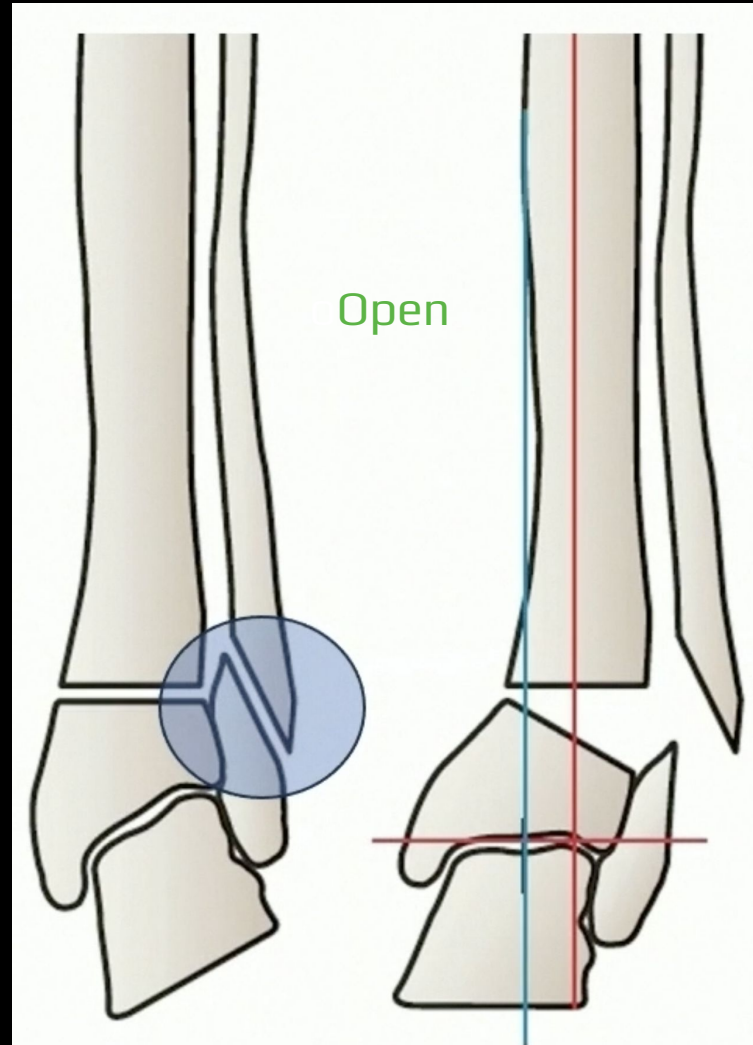
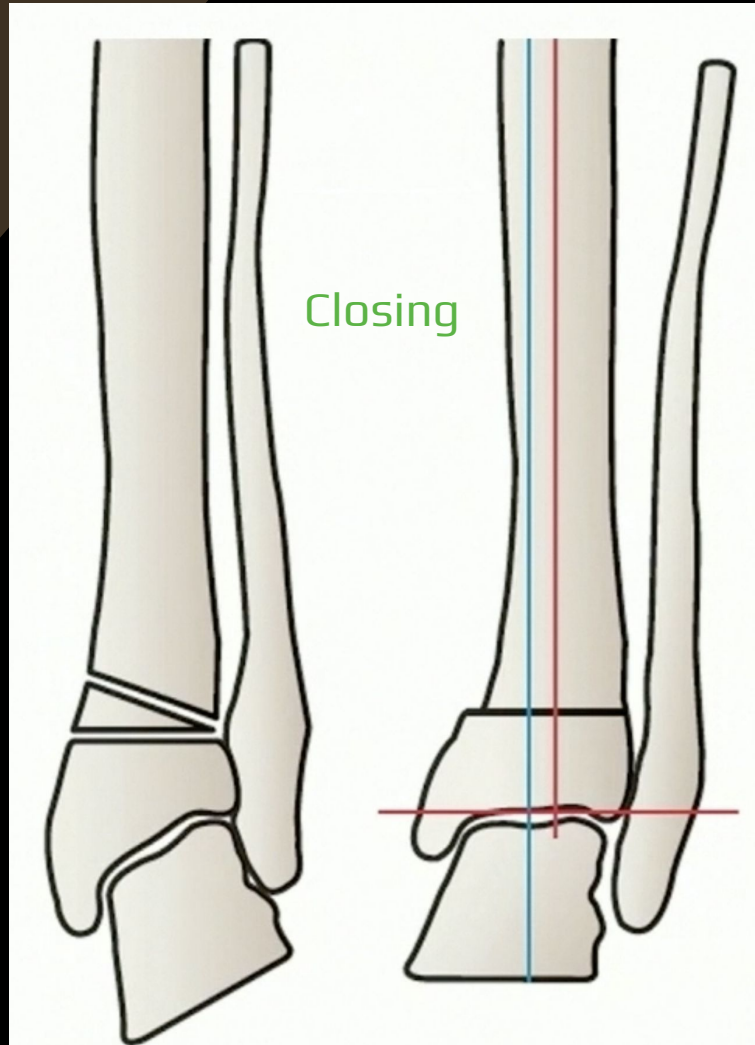
Uitstellen van TEP of Fusie

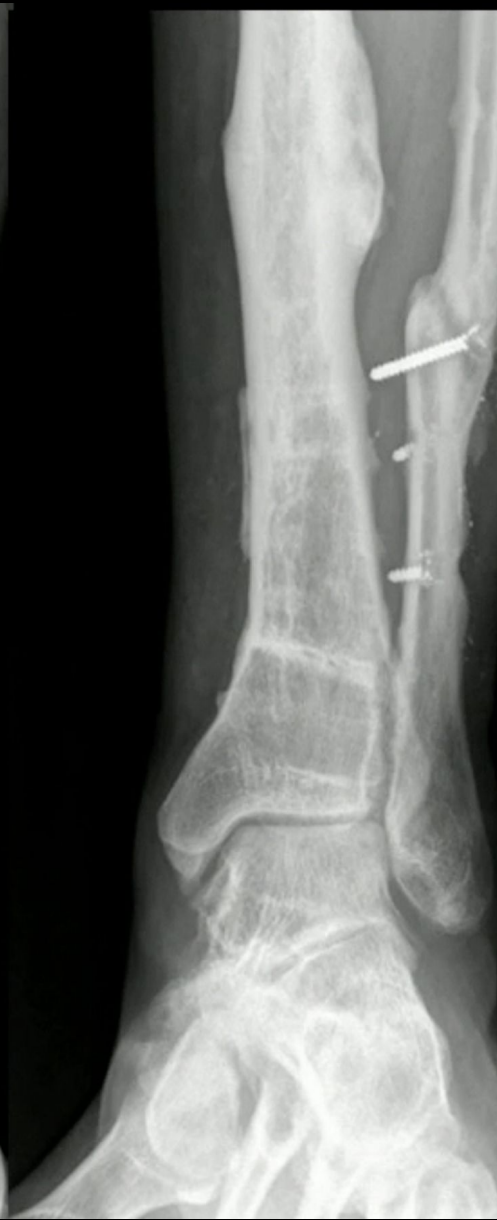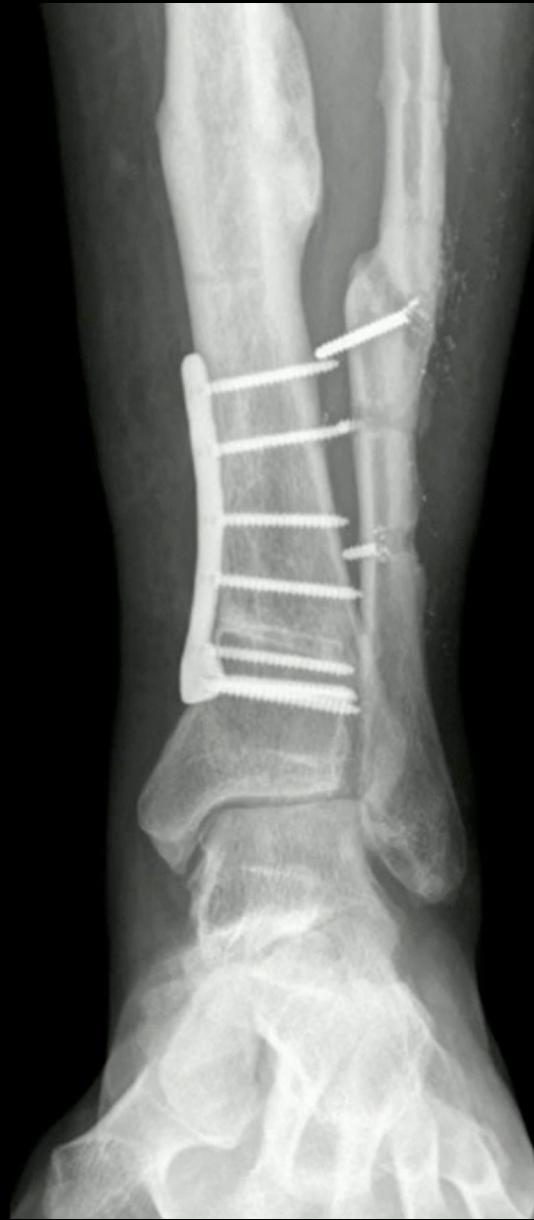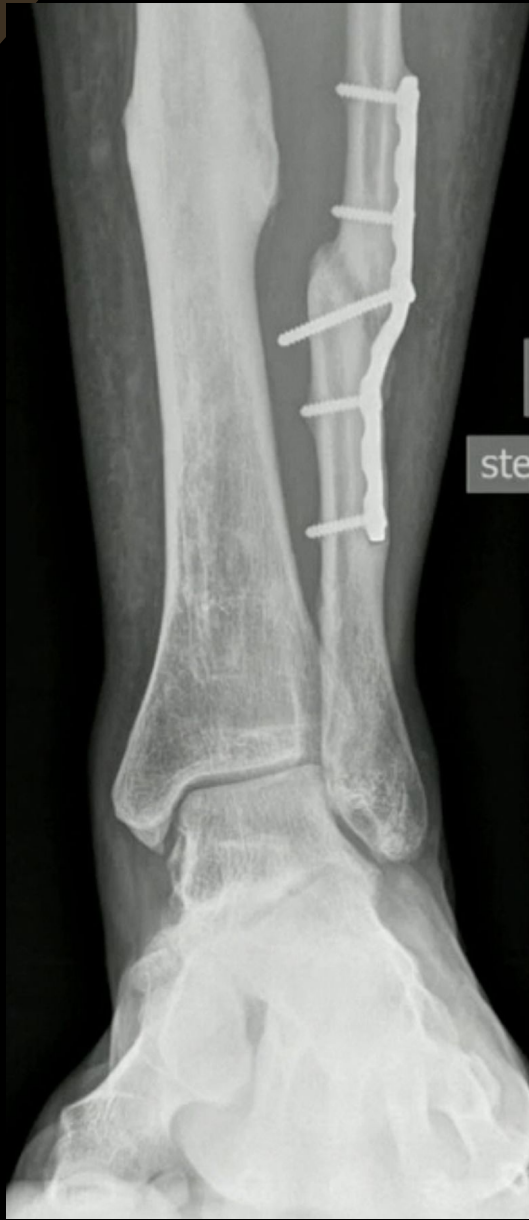Osteotomieën rond de enkel

- Supra-malleolair, boven de enkel
- Infra-malleolair, onder de enkel
 - t.h.v. het hielbeen en/of voorvoet

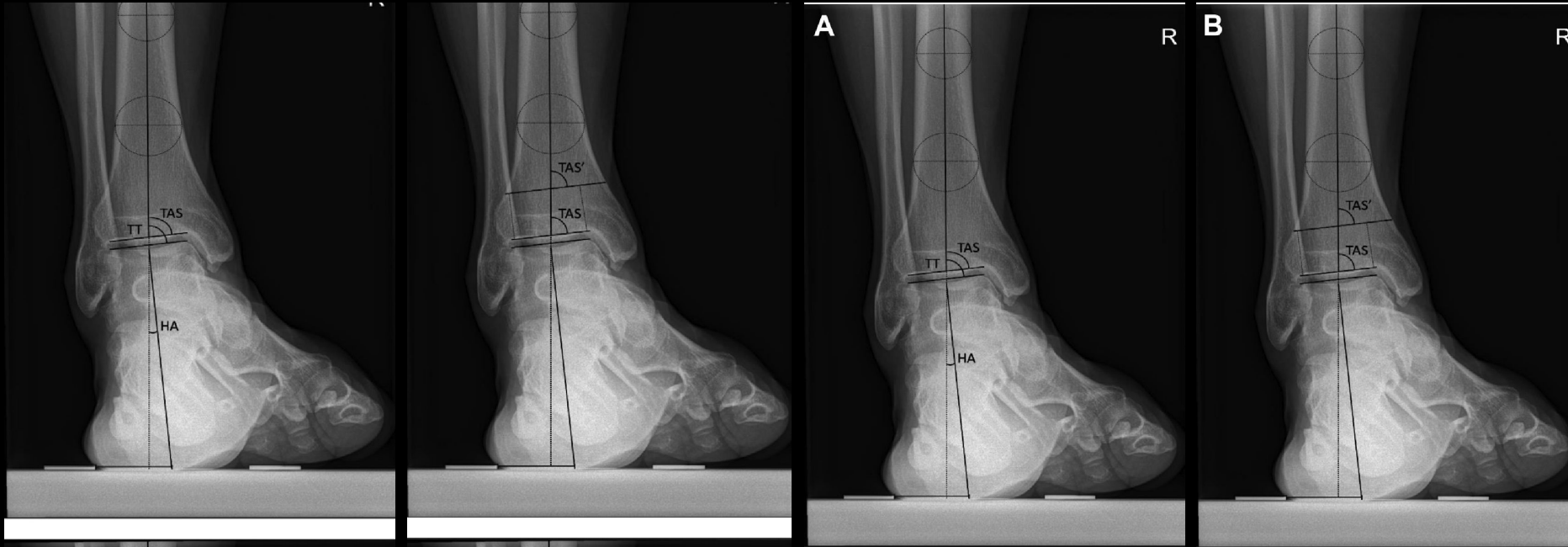


Supra-malleolaire osteotomieën





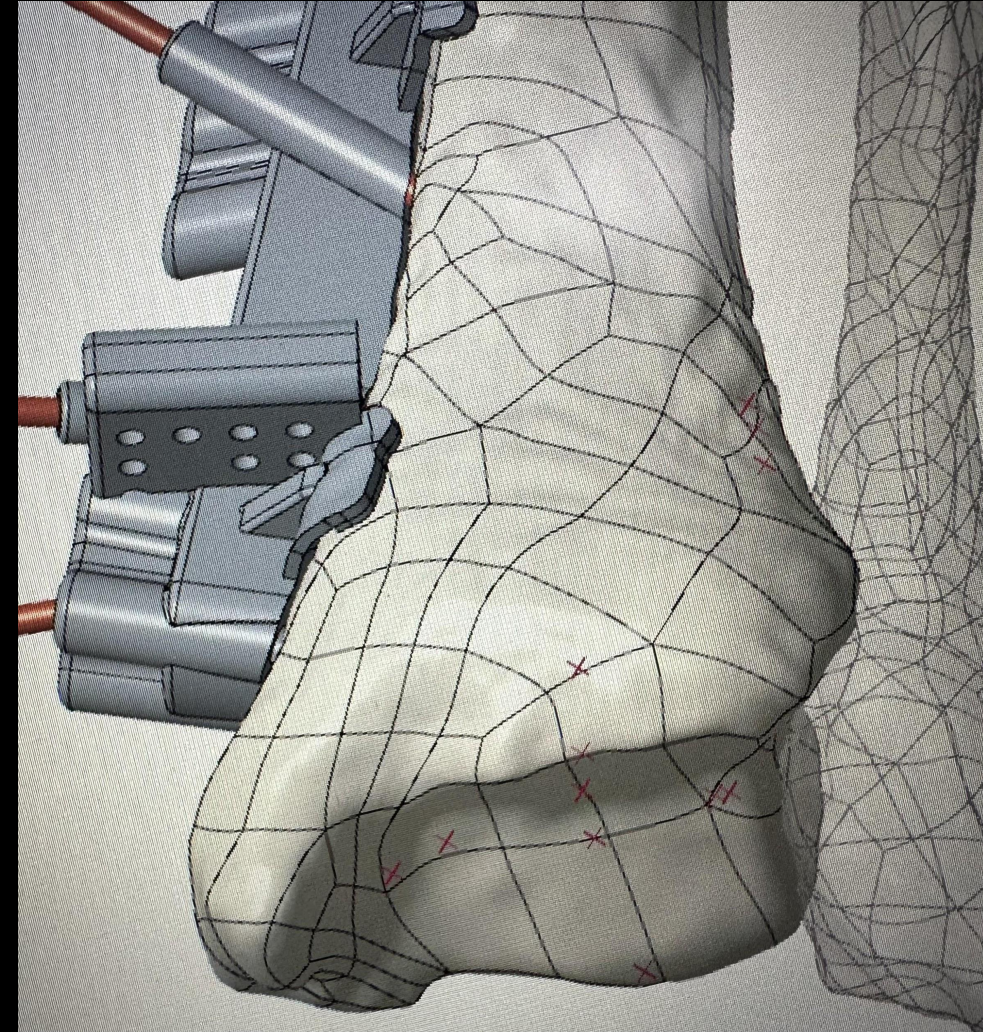
Metingen

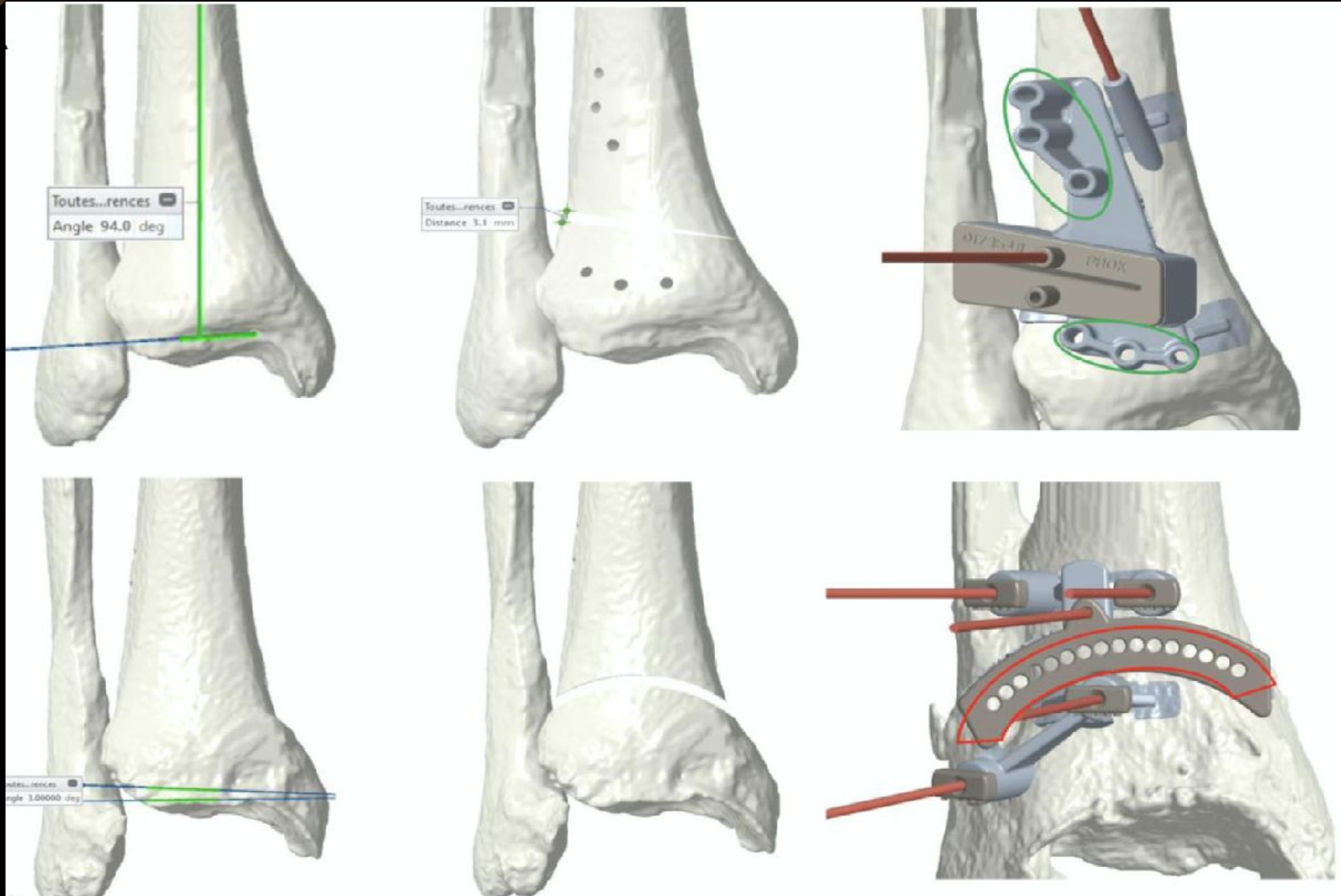


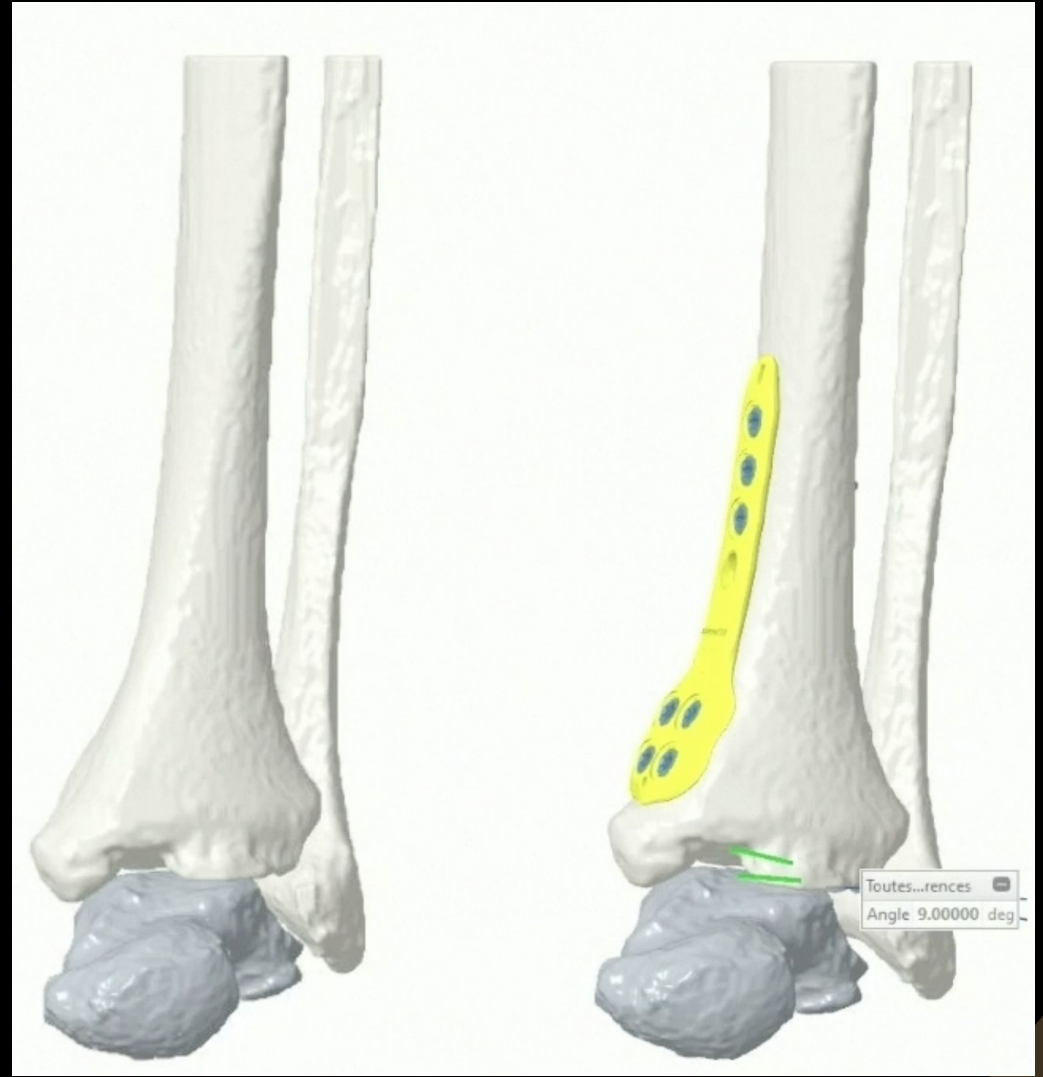
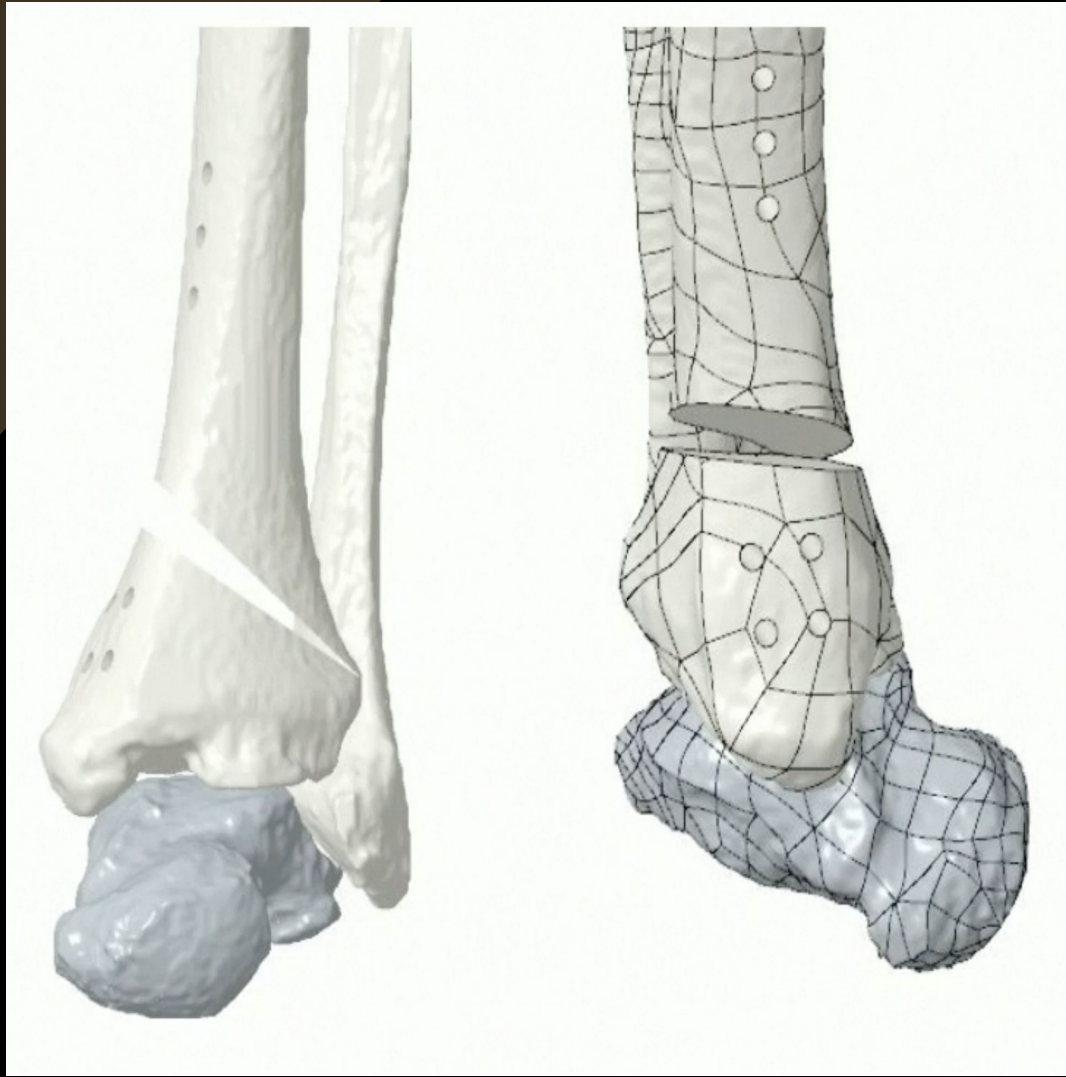
Arne Burssens, MD, Phd, Bernhard Devos Bevernage, MD, Kristian Buedts, MD
Supramalleolar Osteotomies in Cavovarus Foot Deformity
Foot Ankle Clin N Am 5(2023) 843-856

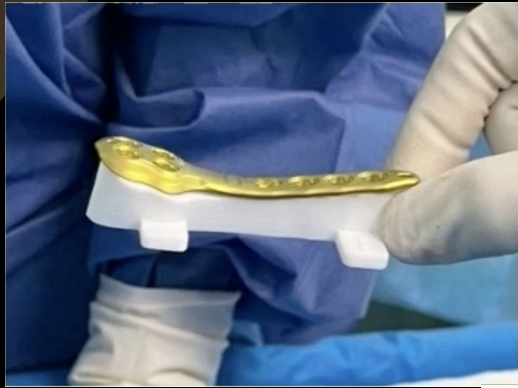
Metingen

- Vroeger 2D
- Nu 3D, met vooral het belang van de staande CT







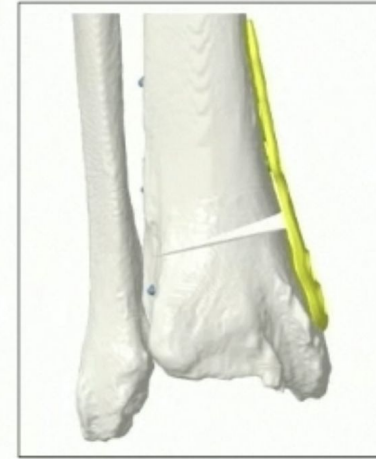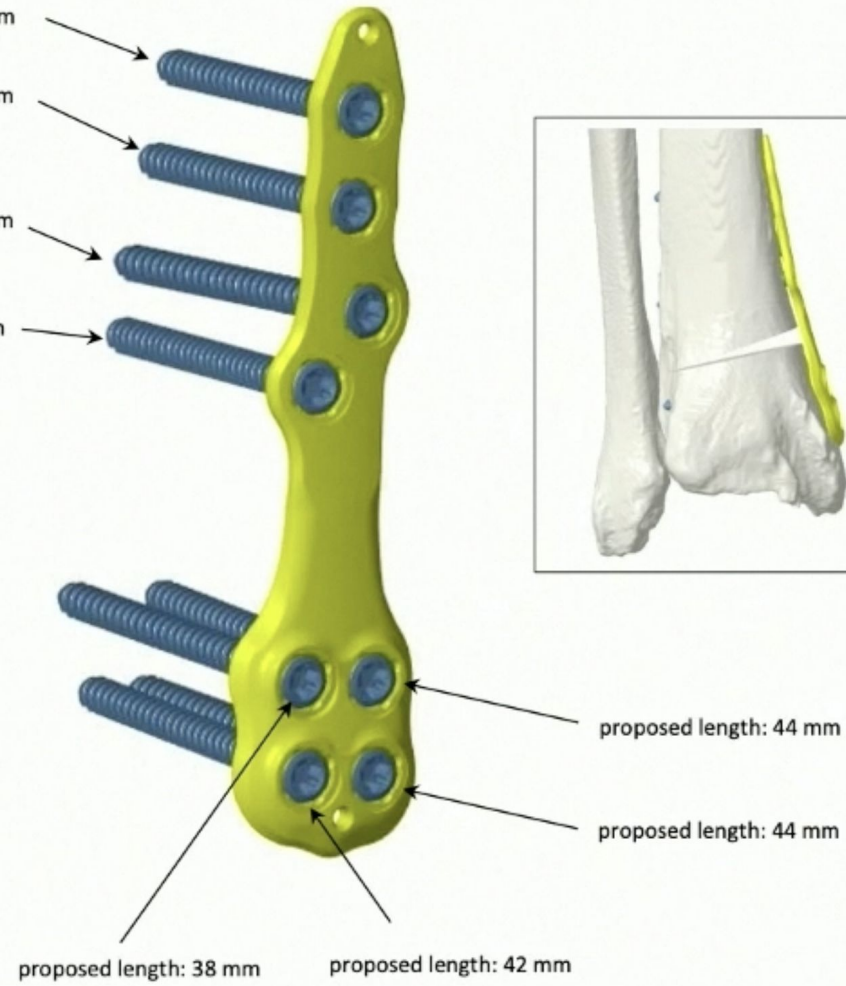
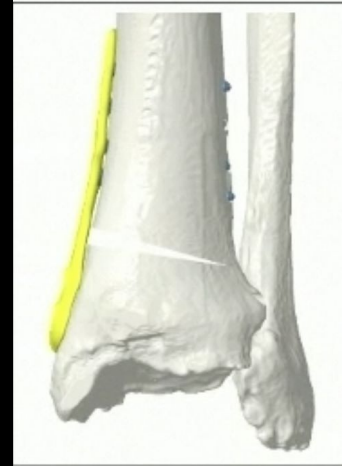


proposed length: 30 mm

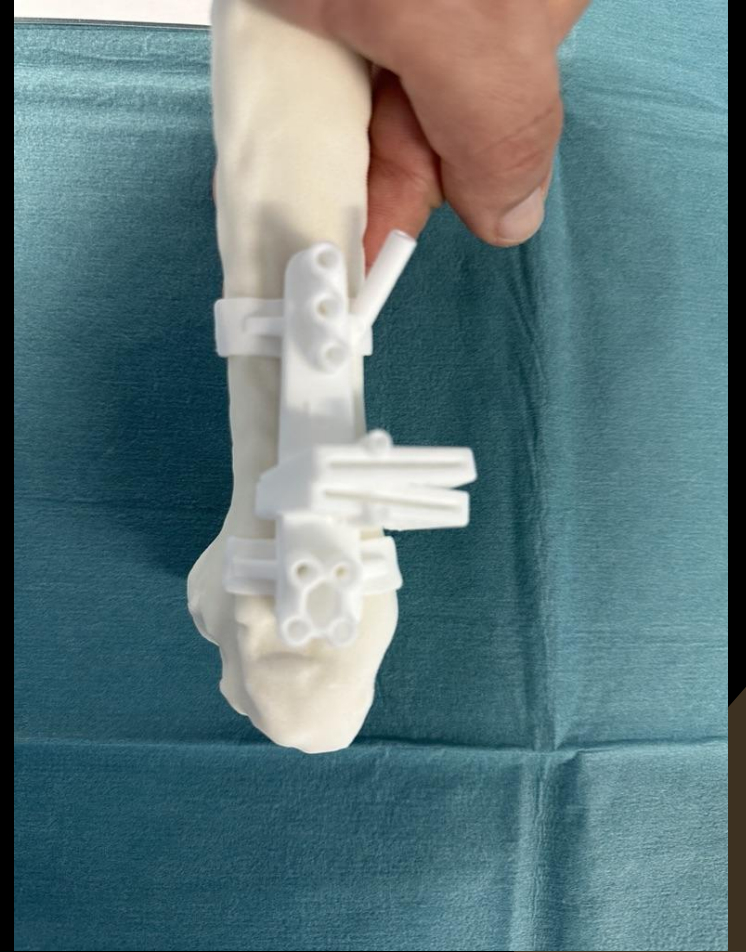
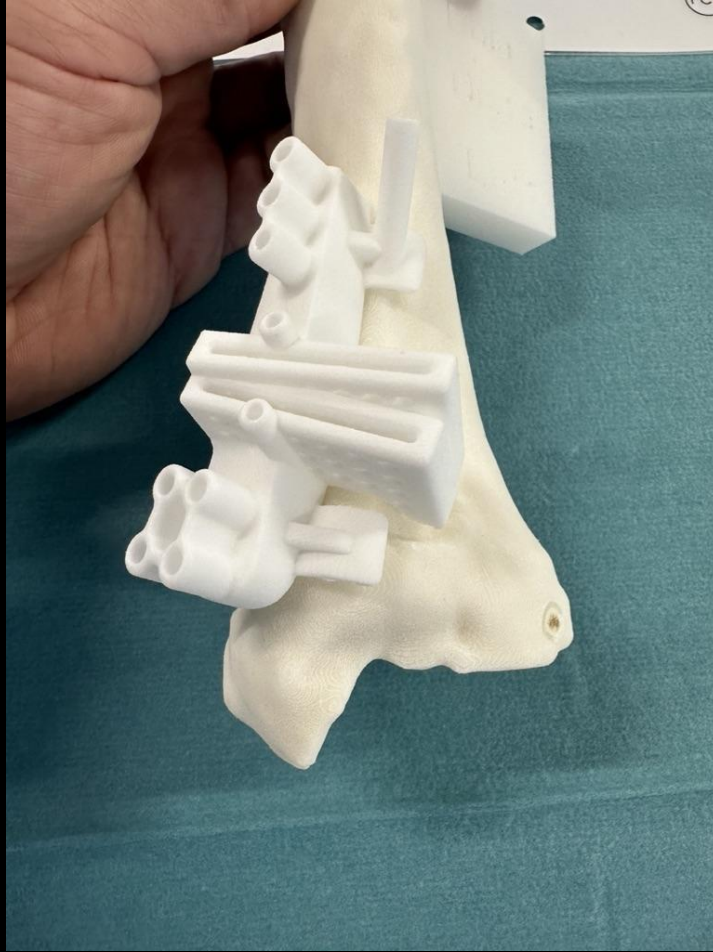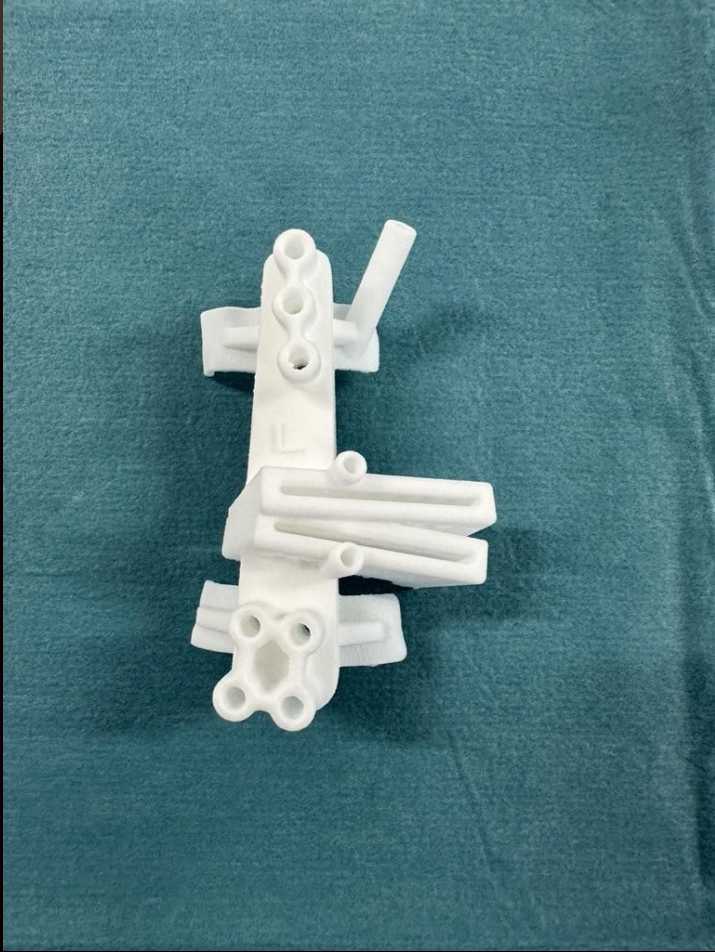
proposed length: 30 mm

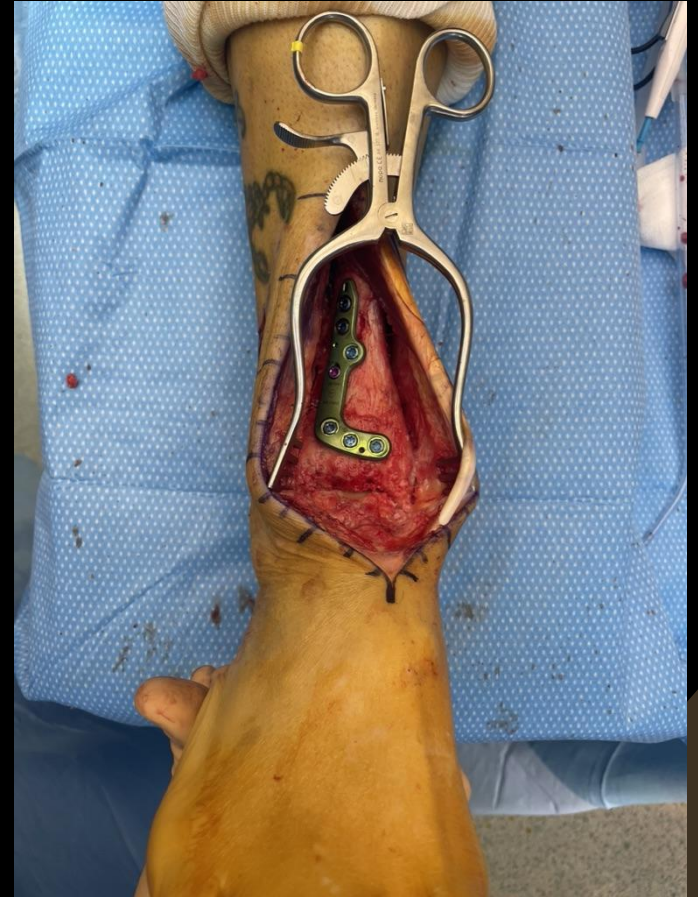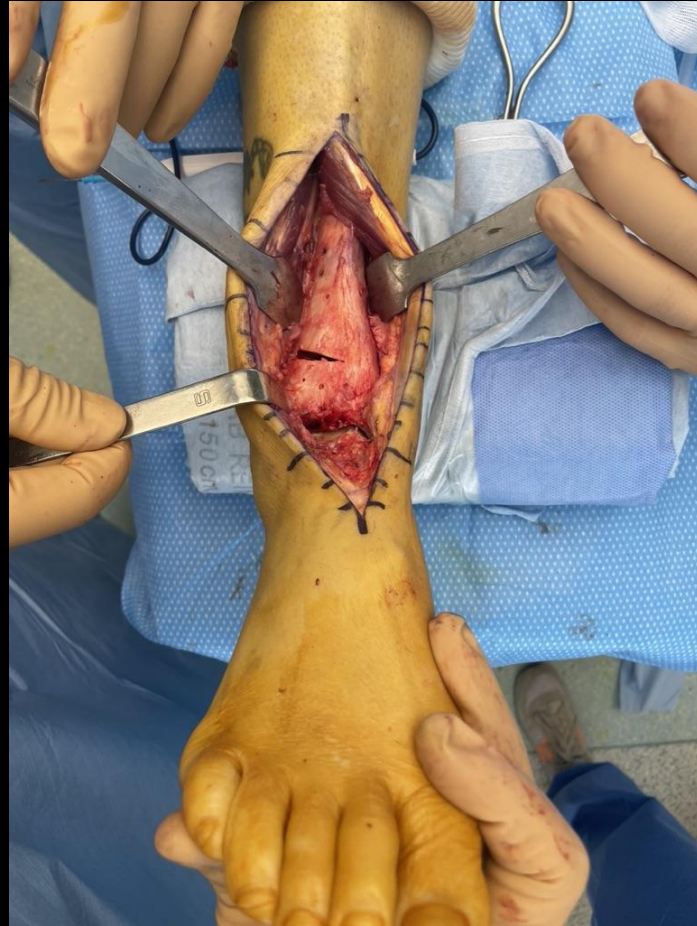
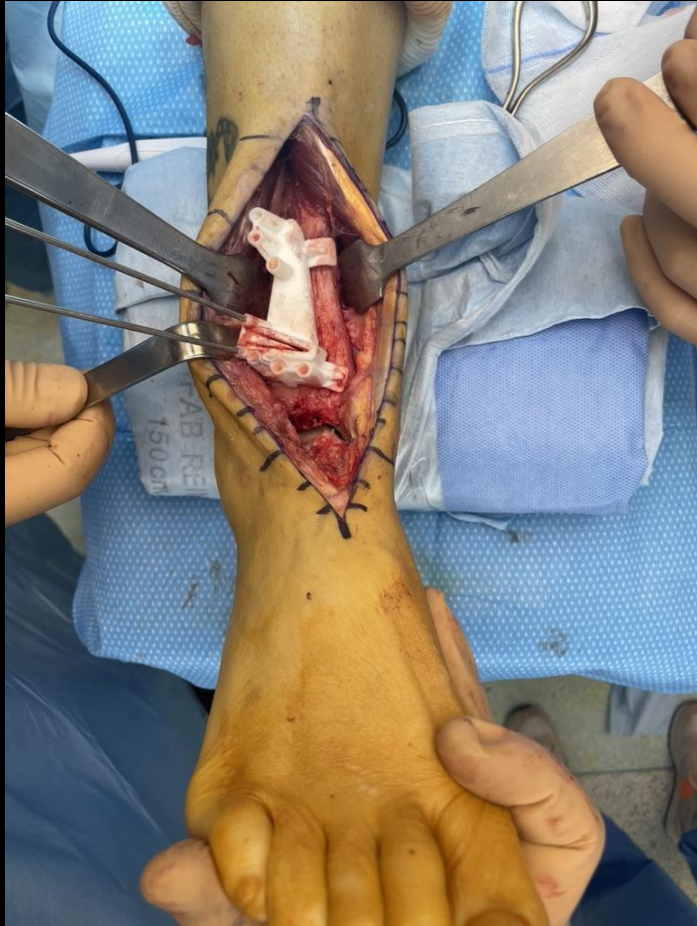
proposed length: 32 mm

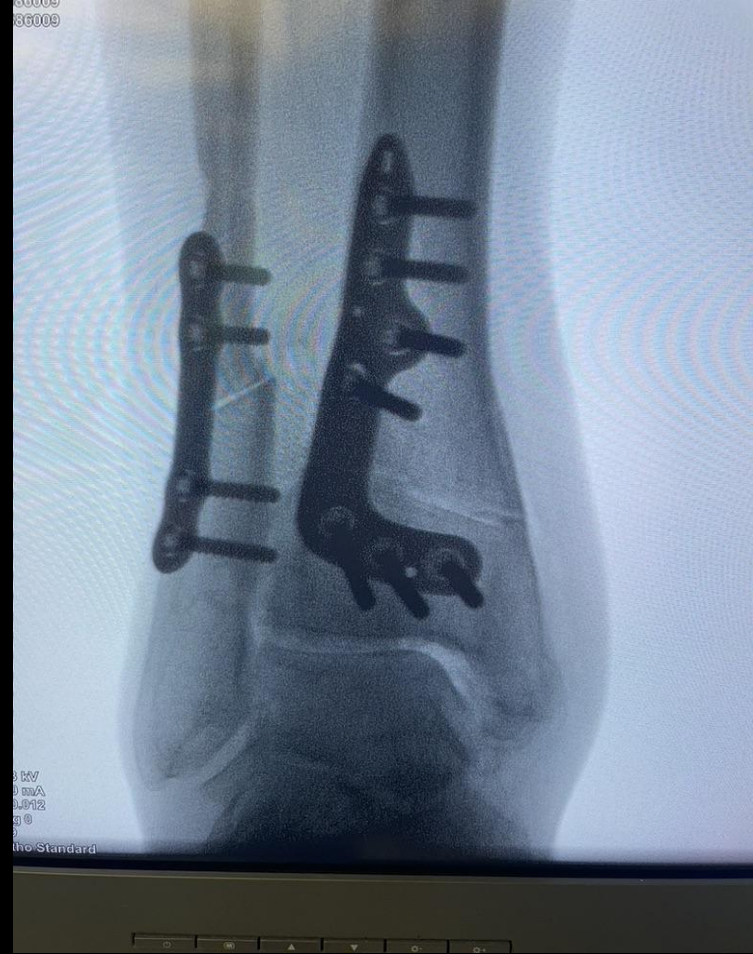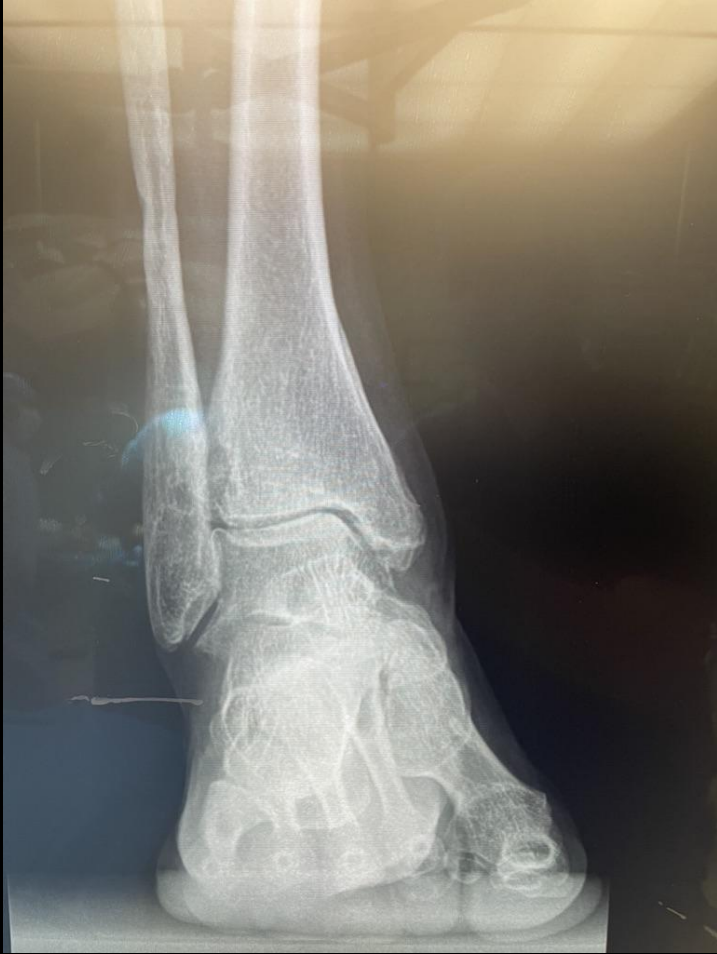proposed length: 34 mm

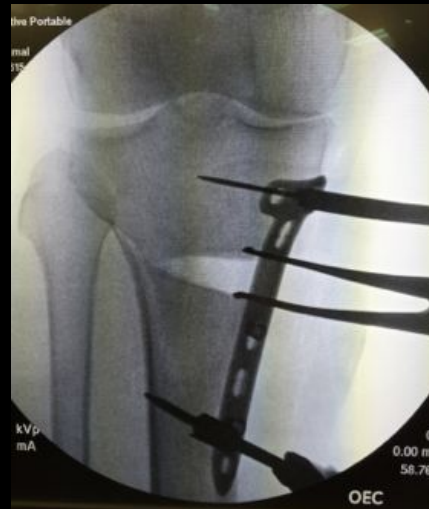
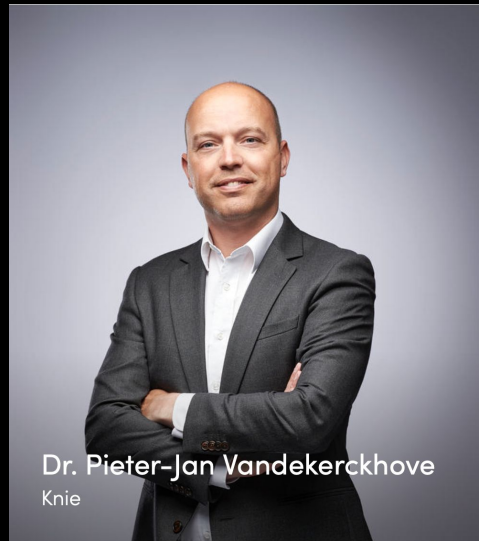
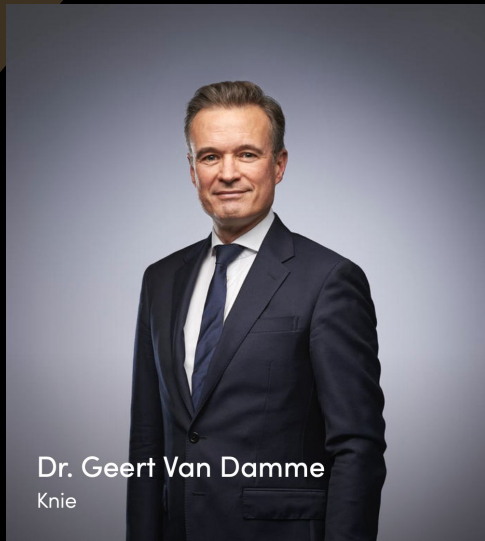
3D-geprint









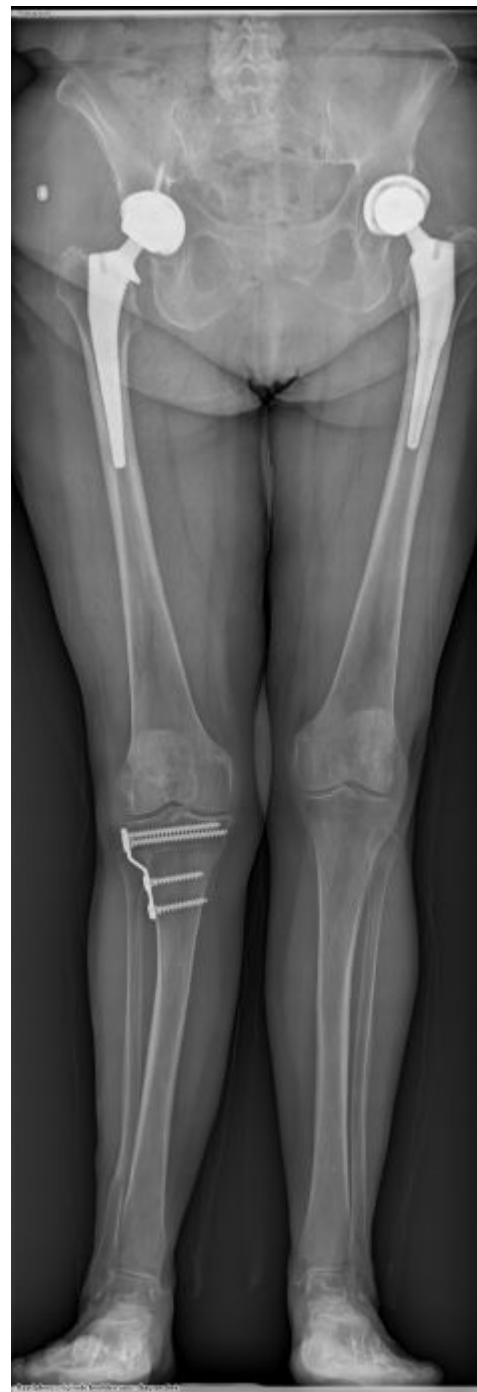
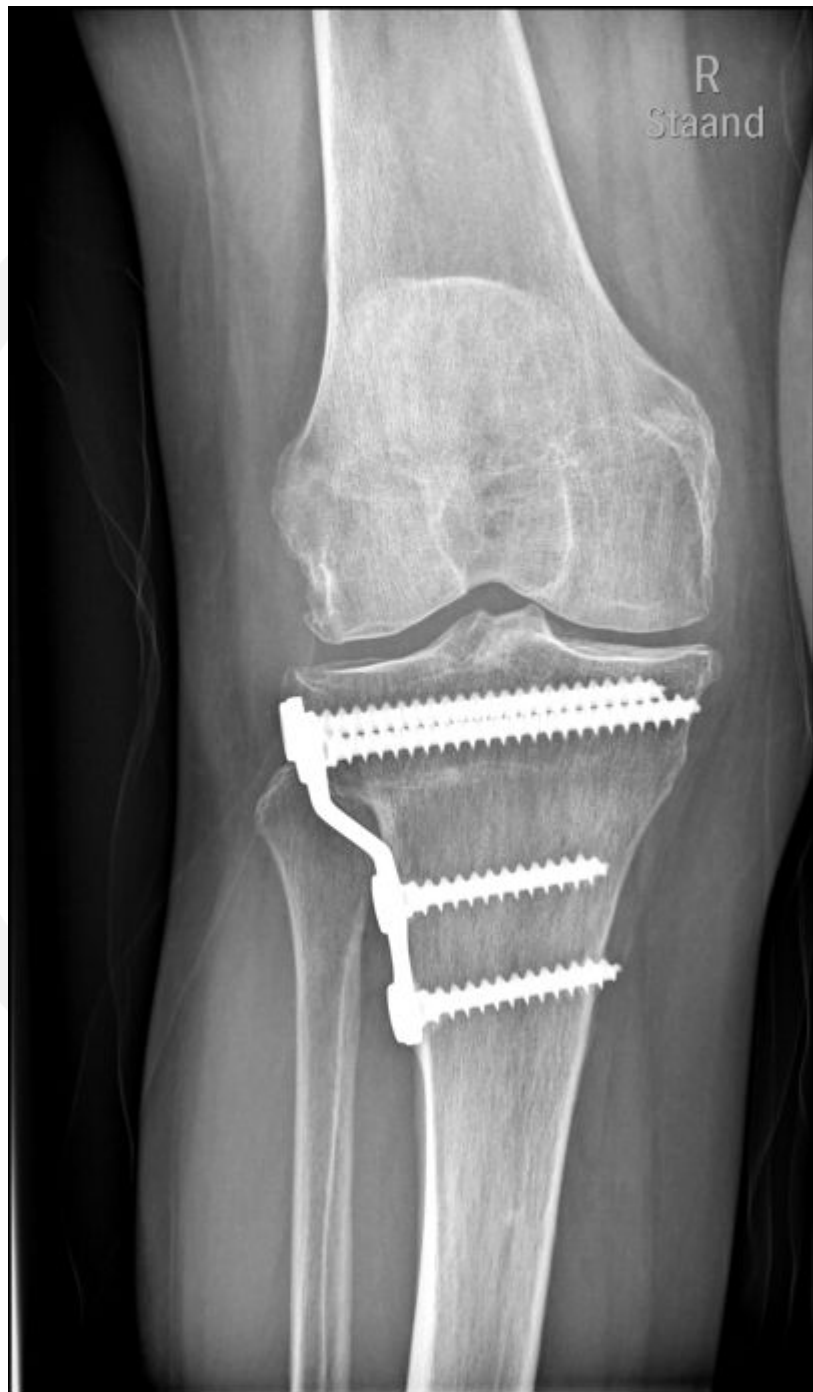
*Alleen ga je
sneller, samen
kom je verder*

Dank Voor Uw
Aandacht

Knee cases Osteotomy PSI

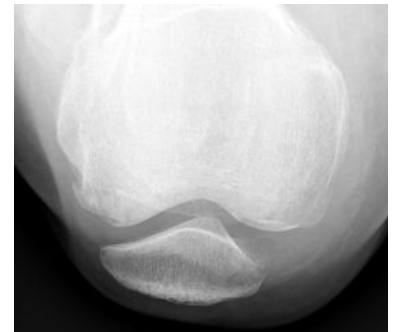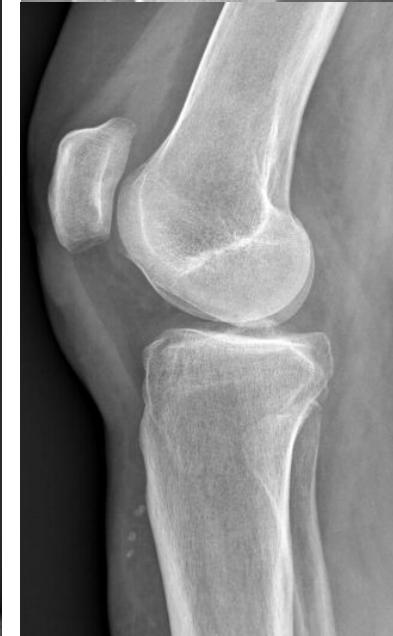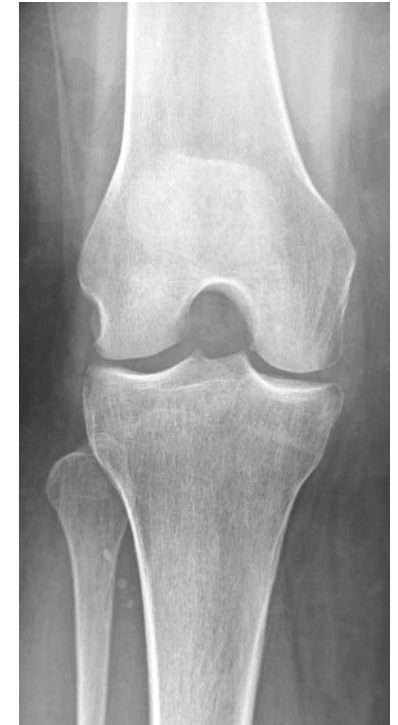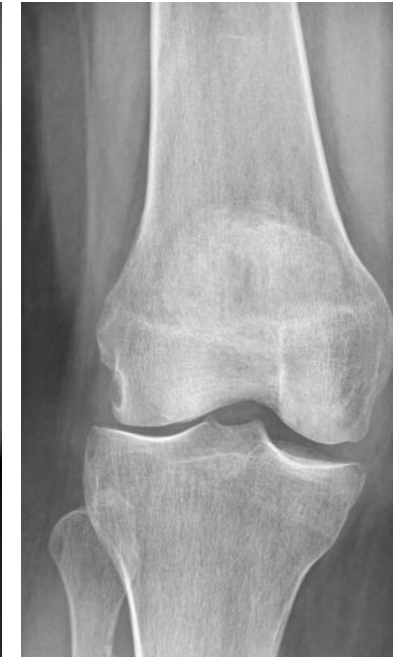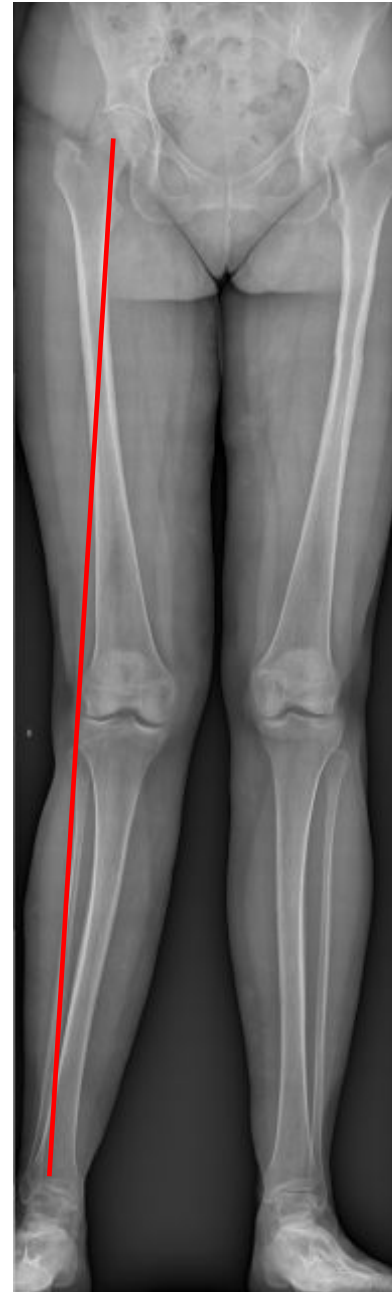G. Van Damme
P-J. Vandekerckhove
L. Beckers







53-jarige dame – bediende

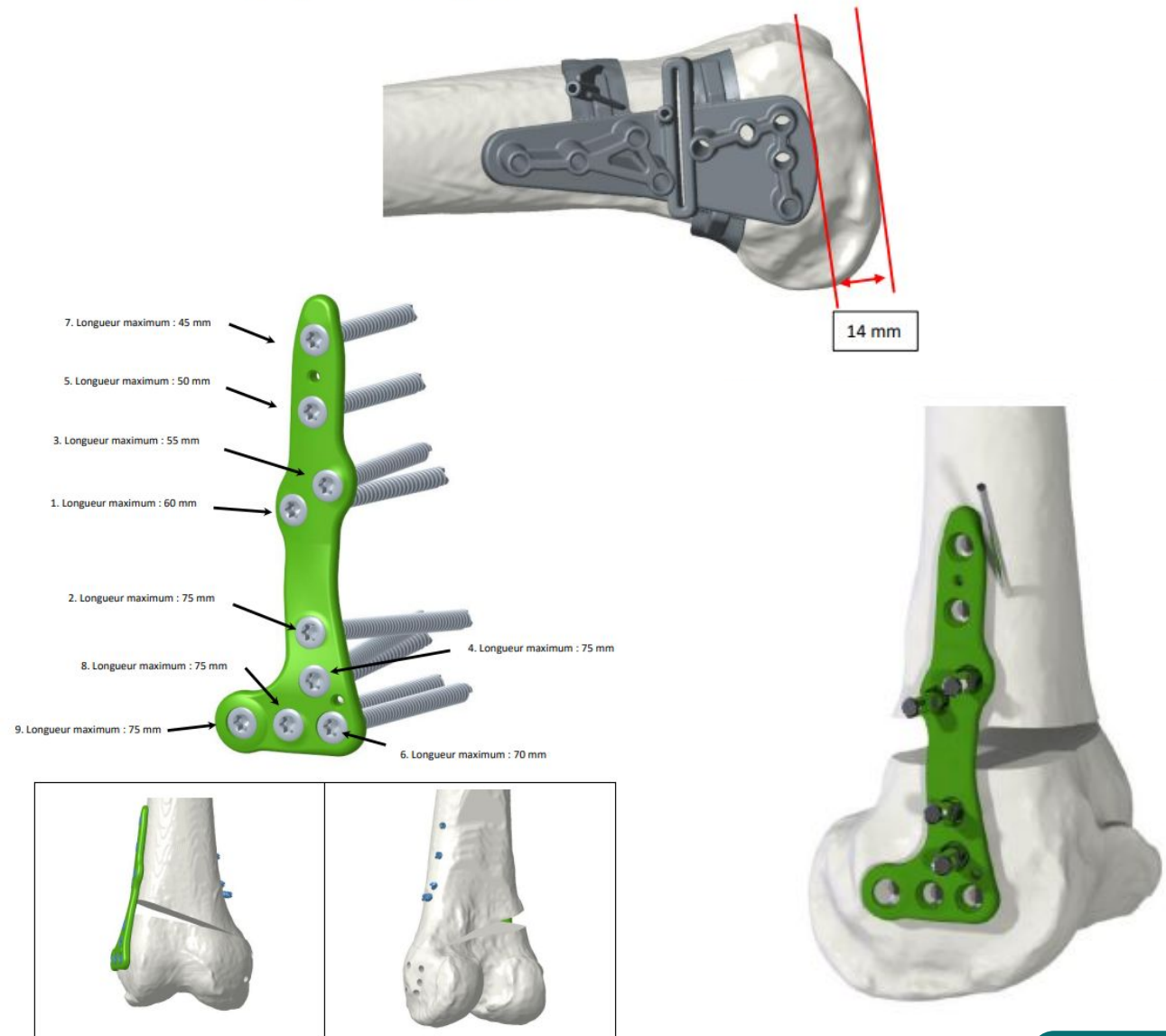
Chronische laterale gonalgie

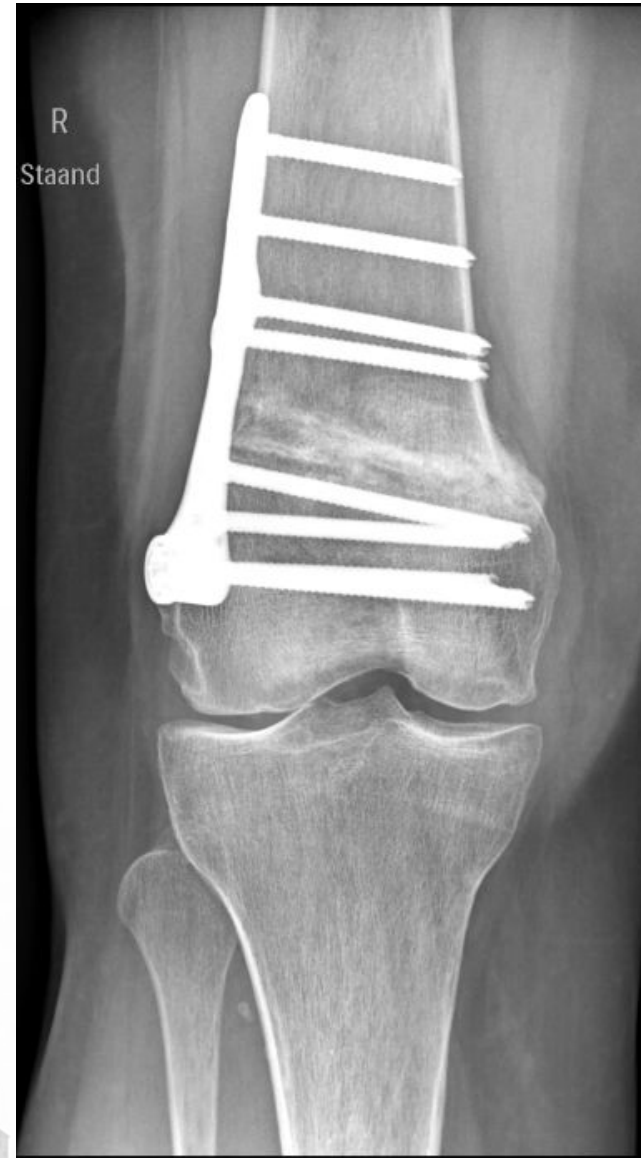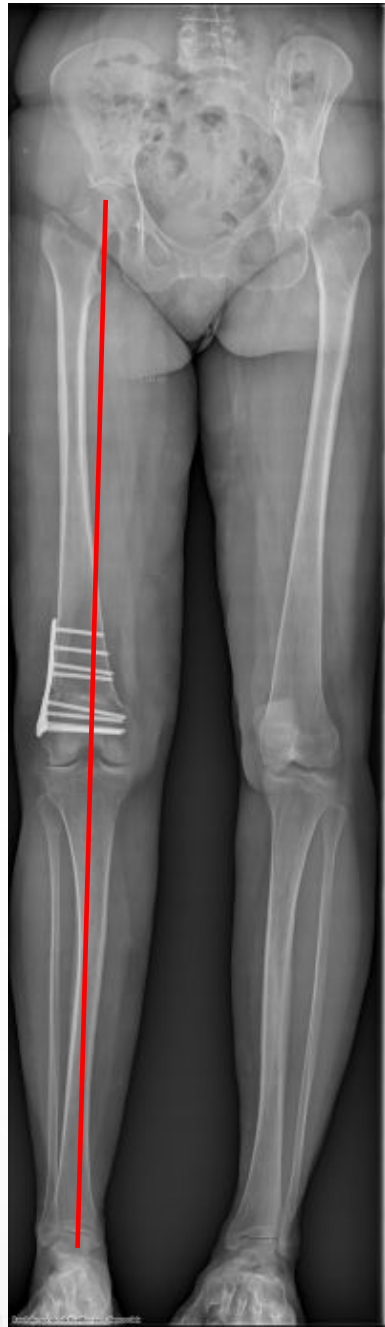
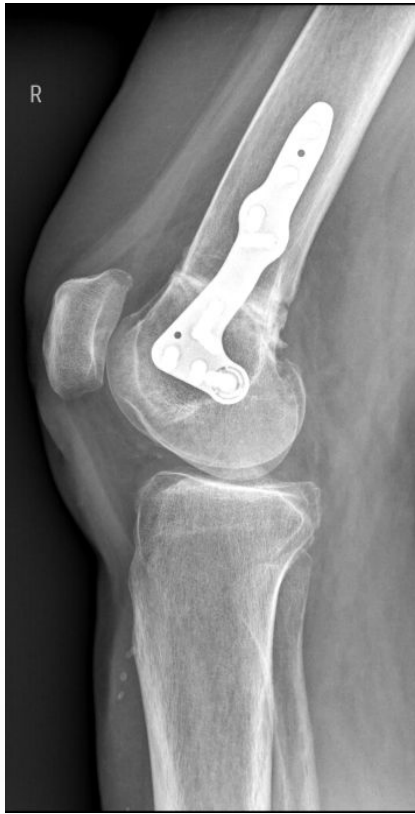Tijdelijk beter met
variserende brace,
kinesitherapie en infiltraties



Résultats postopératoires :

	Préopératoire	Postopératoire
Plan Frontal		
Plan Sagittal		

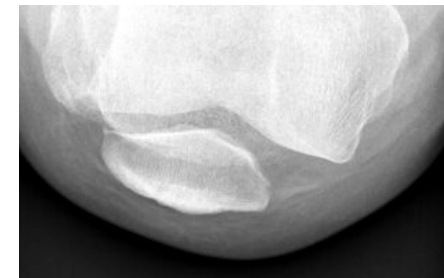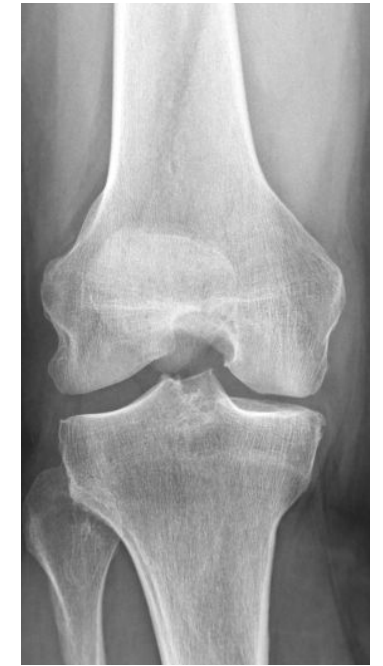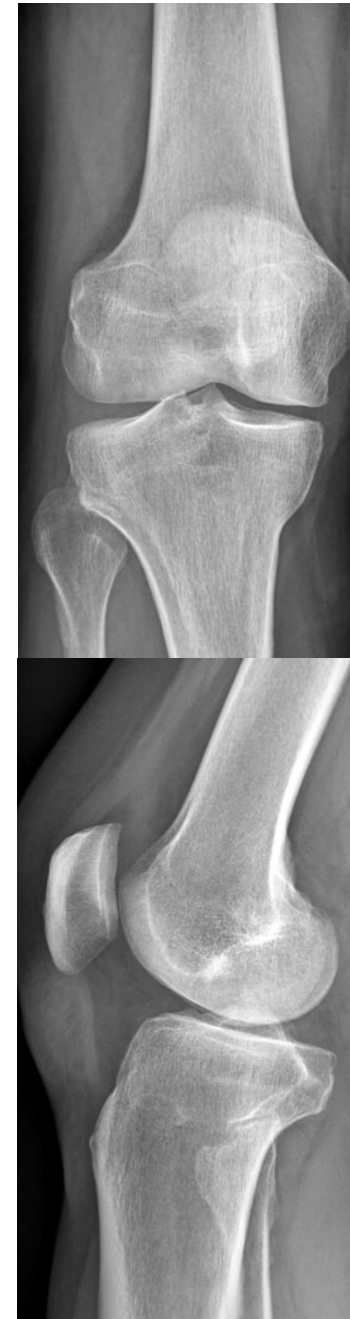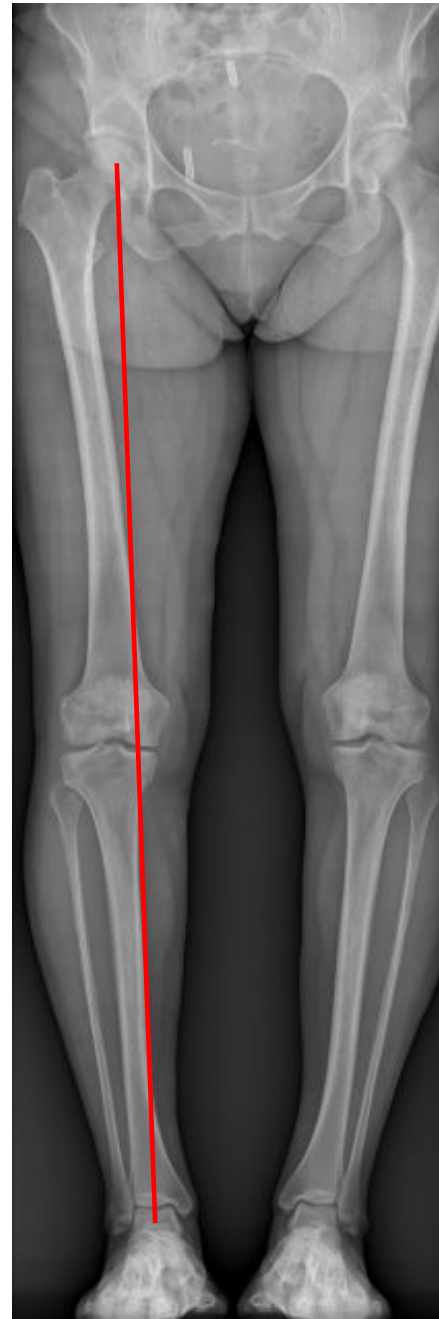




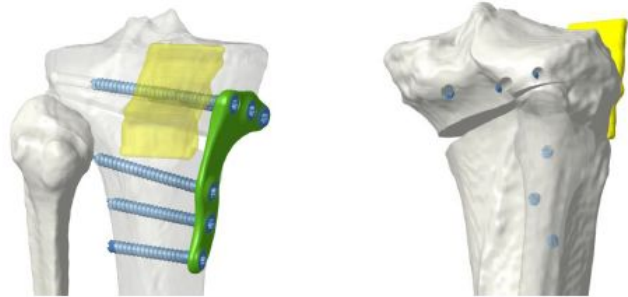
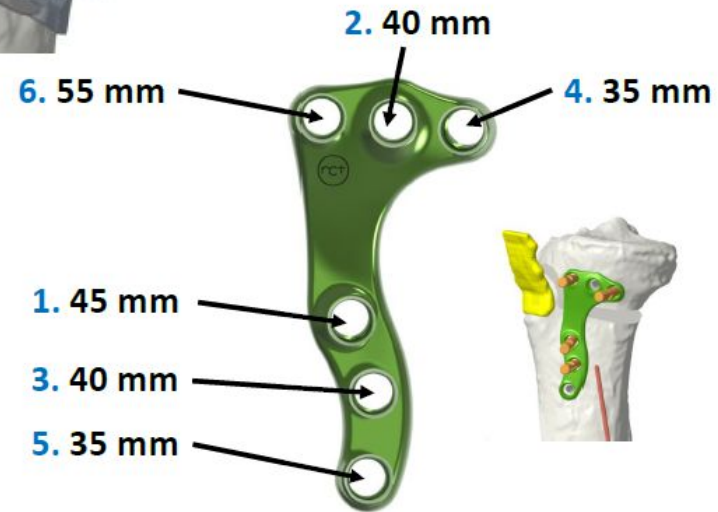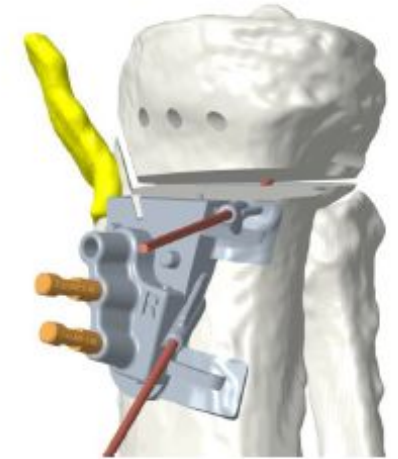
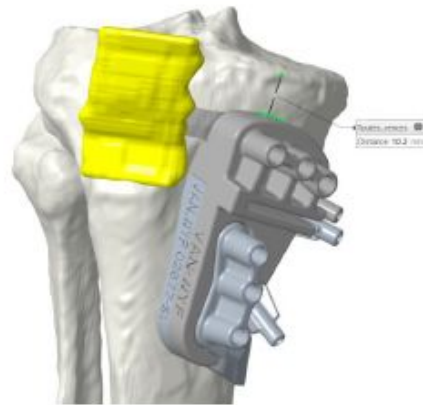
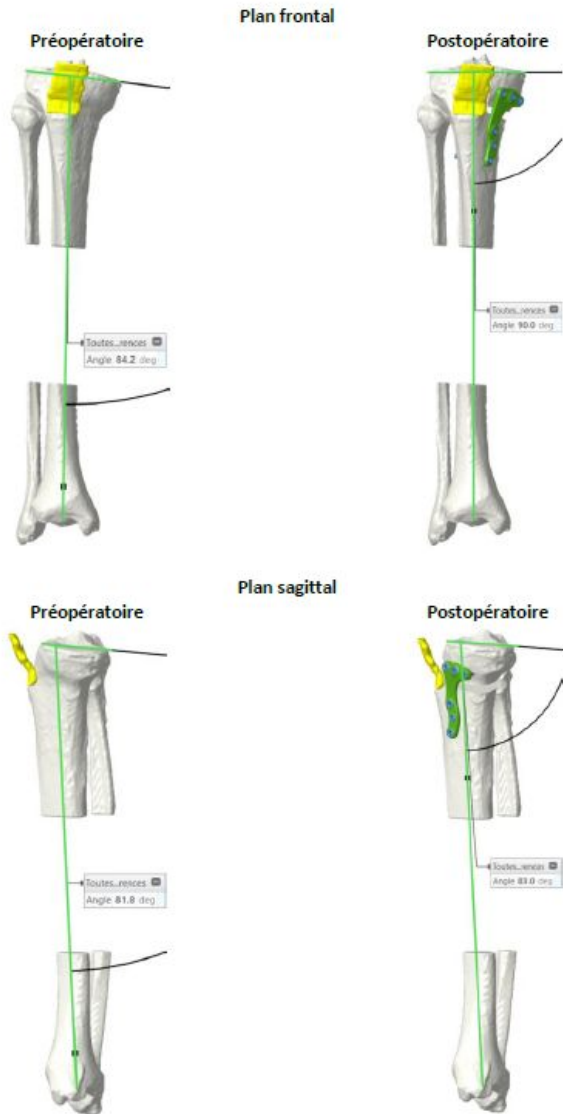
50-jarige dame
bediende – atletiek

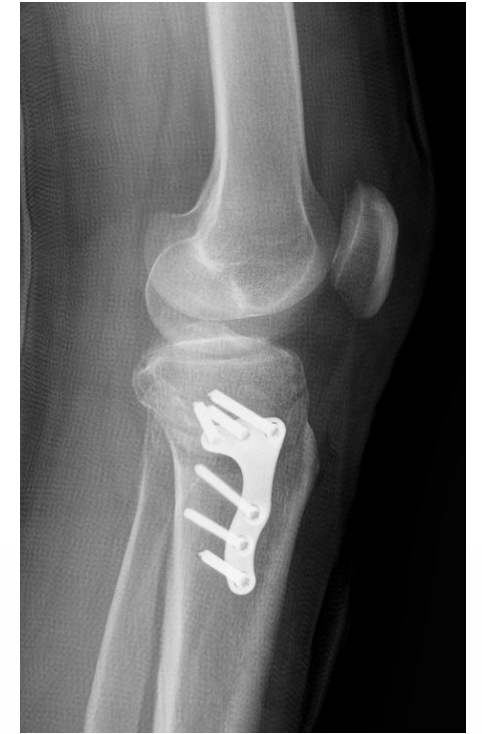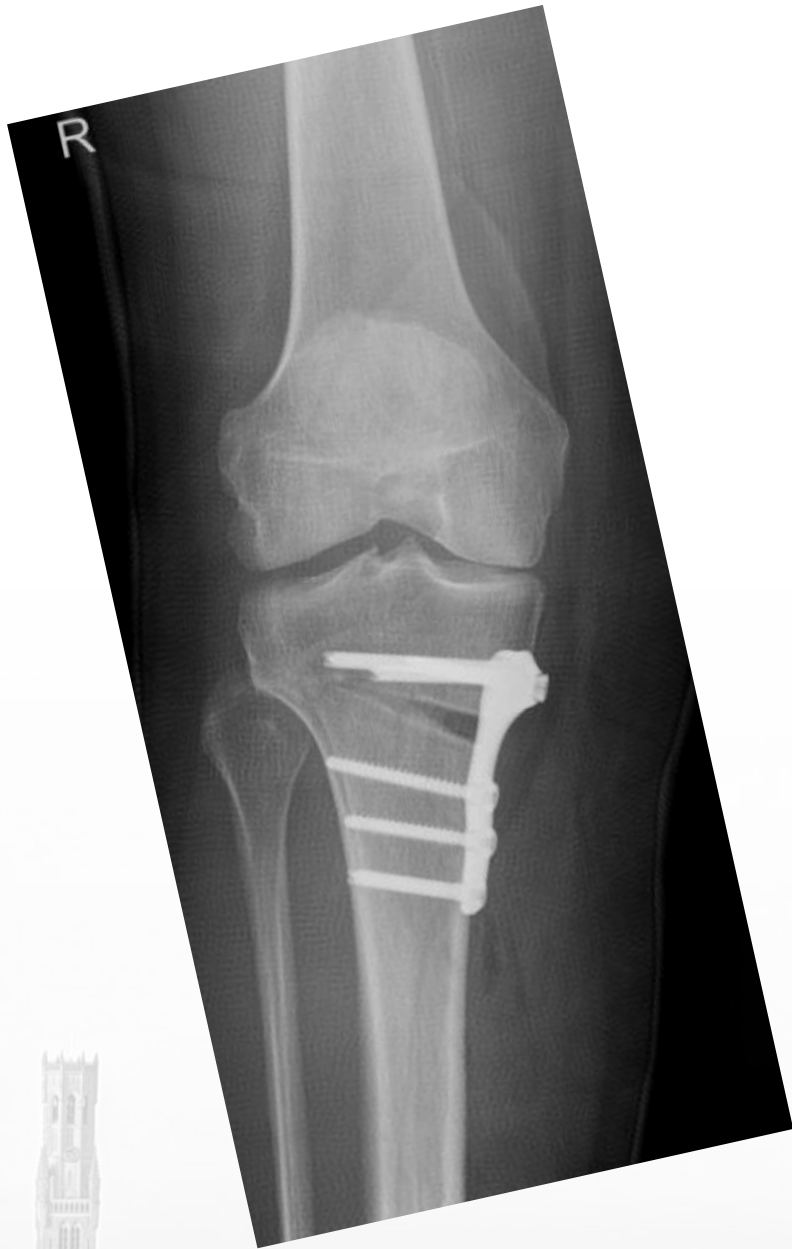Chronische mediale gonalgie

Tijdelijk beter na valgiserende
brace en infiltraties



ANGLES PRÉOPÉRATOIRES ET POSTOPÉRATOIRES

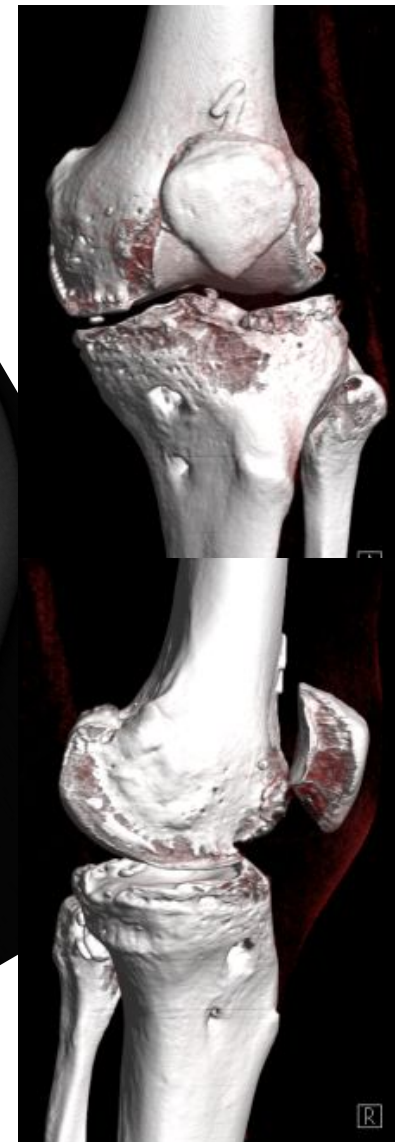
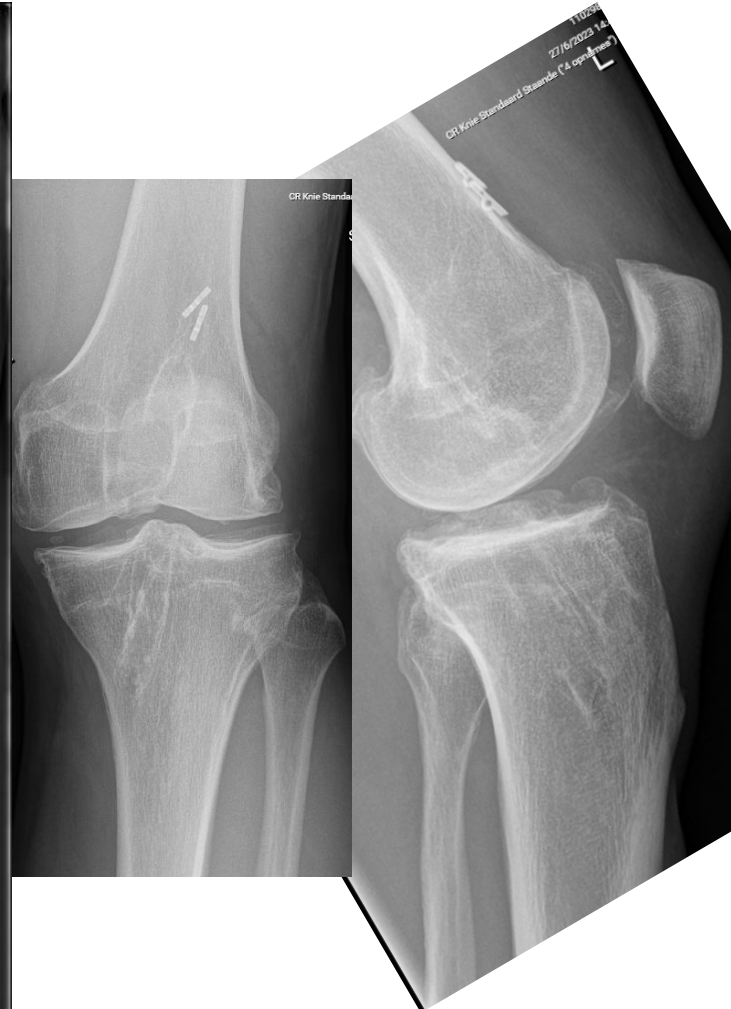
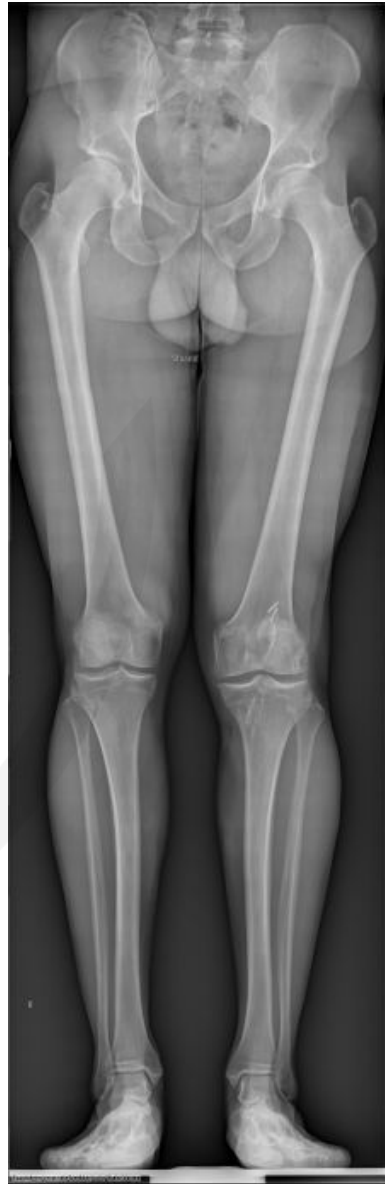


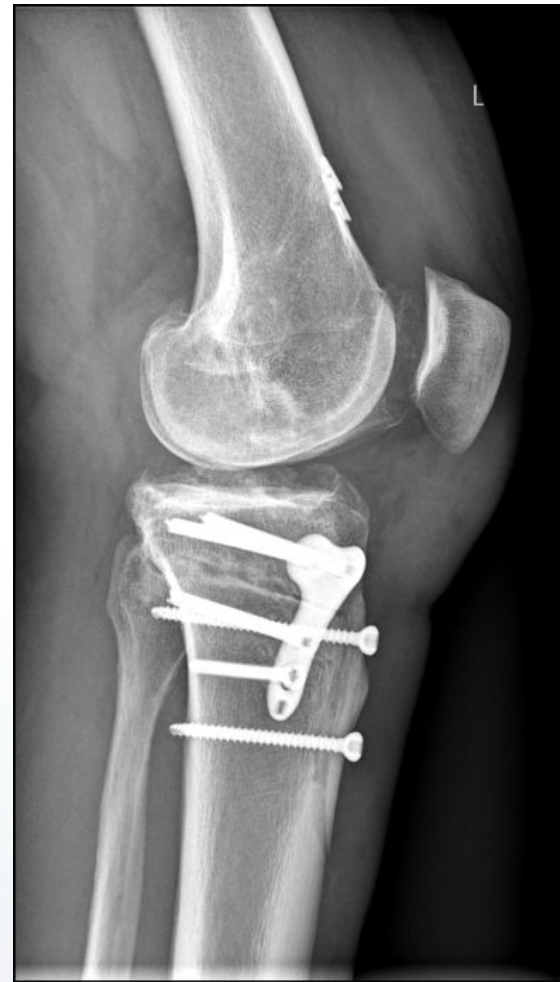
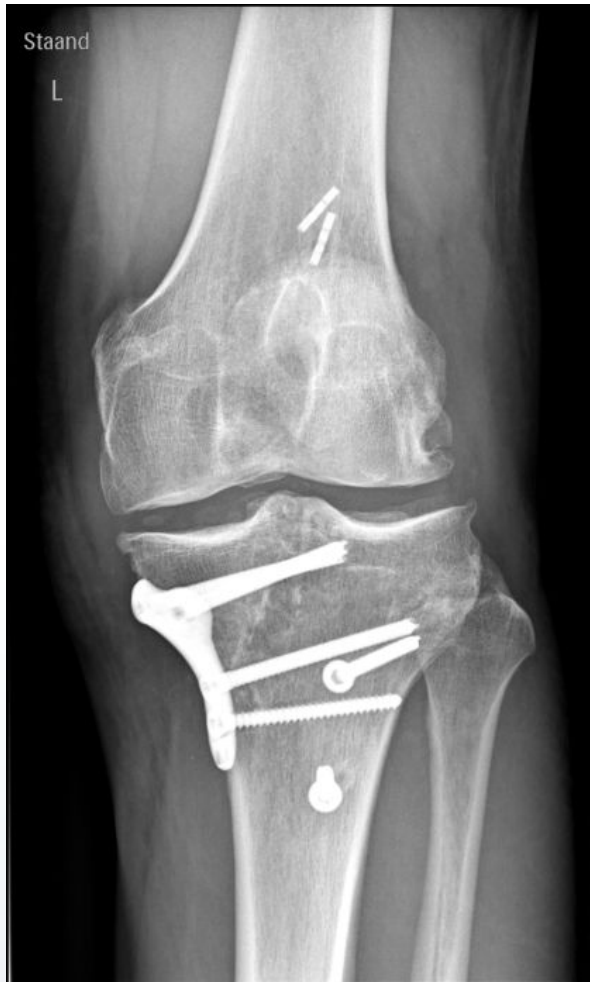37-jarige sportleerkracht

3 x gefaalde VKB-recon

pijn - instabiliteit





ortho
clinic
BRUGGE

